



Received: October 15, 2024

Revised: November 26, 2024

Accepted: January 7, 2025

Corresponding Author:

Warit Powcharoen, Department of Oral and Maxillofacial Surgery, Faculty of Dentistry, Chiang Mai University, Chiang Mai 50200, Thailand
E-mail: warit.p@cmu.ac.th

The Accuracy of In-house Personalized Surgical Cutting Guide for Segmental Mandibulectomy: A Proof of Concept *In Vitro* Study

Chinnakrit Suttitumrongsawat¹, Wannakamon Panyarak², Hanpon Klibngern^{3,4}, Krit Khwanngern^{5,6}, Warit Powcharoen⁷

¹Graduate School, Faculty of Dentistry, Chiang Mai University, Thailand

²Division of Oral and Maxillofacial Radiology, Department of Oral Biology and Oral Diagnostic Sciences, Faculty of Dentistry, Chiang Mai University, Thailand

³Department of Otolaryngology, Faculty of Medicine, Chiang Mai University, Thailand

⁴Department of Plastic and Reconstructive Surgery, Chang Gung Memorial Hospital and Chang Gung University, Taiwan

⁵Department of Surgery, Faculty of Medicine, Chiang Mai University, Thailand

⁶Princess Sirindhorn IT Foundation Craniofacial Center Chiang Mai University, Thailand

⁷Department of Oral and Maxillofacial Surgery, Faculty of Dentistry, Chiang Mai University, Thailand

Abstract

Objectives: Recently, the new computer-assisted surgery workflow for segmental mandibulectomy and reconstruction has been developed. The aim of this study was to evaluate the accuracy of in-house personalized surgical cutting guides for osteotomy on the mandible prior to reconstruction in *in vitro* study.

Methods: Twenty mandibular stereolithography underwent segmental mandibulectomy using the personalized surgical cutting guides. The virtual surgical plans with randomly generated anatomical defects were developed, and personalized surgical cutting guides were created. The stereolithography of mandible and personalized surgical cutting guides were manufactured with the three-dimensional printer using fuse deposition modelling. The segmental mandibulectomy was carried out using the personalized surgical cutting guide. The accuracy of osteotomy was determined using the superimposition between virtual surgical simulation data and scanned images of postoperative stereolithography in software. The error of osteotomy was evaluated in terms of absolute angular and distance deviation.

Results: After superimposition, the mean absolute angulation deviation of osteotomy was 1.3835 ± 0.2357 degrees (95%CI; 1.3081-1.4588) and the mean absolute distance deviation of osteotomy was 1.2975 ± 0.2907 mm (95%CI; 1.2045-1.3904).

Conclusions: The in-house personalized surgical cutting guides provided acceptable accuracy and feasibility for osteotomy on mandible. Further investigation in terms of clinical benefits is needed.

Keywords: computer assisted surgery, mandibular reconstruction, surgical cutting guide, three-dimensional printing, virtual surgical planning

Introduction

Segmental mandibulectomy is a surgical procedure that removes pathology from the mandible along with part of the surrounding tissue, resulting in bone continuity defects that must be restored. Mandibular reconstruction aims to restore the lower facial contour and abilities to masticate, swallow, and articulate. Numerous treatment options for mandibular reconstruction following segmental mandibulectomy have been proposed, including mandibular reconstruction plates with or without soft tissue flaps (no osseous reconstruction), nonvascularized bone grafts, and vascularized bone flaps.^(1,2) Traditional mandibular reconstruction requires the surgeon's precision and skill for optimal osteotomy, bone segmentation, and modeling, based on intraoperative decisions. Subsequently, either intraoperatively bending plates or pre-bending plates on rapid prototype models are used to secure the remaining parts of the mandible and bone grafts.

The significance of surgical margins on both bone and soft tissue in the pathological ablation of the mandible has consistently generated substantial scientific interest. Traditionally, surgeons rely on inaccurate measurement techniques to establish safety margins during clinical procedures. Preoperative medical imaging has been used for planning the surgical margin without any tools transferring this information directly to surgery. Intraoperatively, the assessment of surgical margins depends on the surgeon's visualization, tactile perception, ability to estimate the tumor extension on the preoperative imaging, and anatomical understanding.

Computer-assisted surgery (CAS) is a procedure encompassing various types of technologies. This workflow is becoming increasingly prevalent globally and plays a crucial role in ablative and reconstructive surgery by enhancing the precision of osteotomy and graft positioning. Although computer-assisted mandibular reconstruction has shown increased efficiency in terms of accuracy and overall surgical outcomes^(3,4), various barriers to its adoption have arisen worldwide. The in-house development of these workflows will enable institutions to design, manufacture, and conduct procedures under the CAS concept with their specific settings and limitations. The Department of Oral and Maxillofacial Surgery, Faculty of Dentistry, Chiang Mai University has been using CAS, consisting of virtual surgical planning and additive manufacturing, in various types of surgery.

Recently, the concept of an in-house CAS workflow has been developed for segmental mandibulectomy and mandibular reconstruction with nonvascularized iliac crest bone graft (NVIBG) under the limitations of the setting. The concept of this workflow consisted of computer-assisted planning of mandibulectomy and manufacturing of a personalized surgical cutting guide using a three-dimensional printer (only fuse deposition modeling). With the limitations of available software and additive manufacturing, the institute's surgeon still must pre-blend the mandibular reconstruction plate and intraoperatively segment or model NVIBG. Previous CAS workflows have used an additional surgical cutting guide at the donor site, allowing for segmentation and modeling of either fibular or iliac bone grafts, along with a patient-specific reconstruction plate, which are not the components of our CAS workflow. Moreover, the in-house personalized surgical cutting guide is newly designed, and its efficacy must be proven. Thus, this *in vitro* study aimed to evaluate the accuracy of in-house personalized surgical cutting guides in providing planned osteotomies in mandibular models, ensuring their reliability and feasibility.

Material and Methods

Study design

This *in vitro* study was conducted within the Oral and Maxillofacial Surgery Clinic, Faculty of Dentistry, Chiang Mai University. A surgical cutting guide and virtual surgical planning with mandibular stereolithography were randomly constructed from a set of cone-beam computed tomography (CBCT) images of a patient with a normal mandible, selected by the oral and maxillofacial radiologist. An overview of the study design is illustrated in Figure 1. The study design was approved by the Institutional Ethical Committee, Faculty of Dentistry, Chiang Mai University, Thailand (approval no. 39/2563).

Concept of in-house surgical cutting guide design

The surgical cutting guide was designed through virtual surgical planning in Mimics Research software (Materialise, Leuven, Belgium), aiming to perform a planned mandibular osteotomy and stabilize the remaining parts of the resected mandible in the original position by fixing a pre-bending reconstruction plate and modeling bone graft. This surgical cutting guide also eliminates

the need for intraoperative intermaxillary fixation. The surgical cutting guide consists of three components: (1) the base, (2) the cutting plane, and (3) the axial connector (Figure 2). The base part with a screw hole directly contacts the bony surface and serves as a guide to settle the surgical cutting guide in a predetermined position. This part extends to cover the remaining parts of the resected

mandible, especially the inferior border, and leaves a space for the pre-bending reconstruction plate. The cutting plane part acts as a guide for positioning the surgical saw when performing the mandibular osteotomy, with spared space for a reconstruction plate placement. Lastly, the axial connecting part bridges two cutting plane parts across the defect.

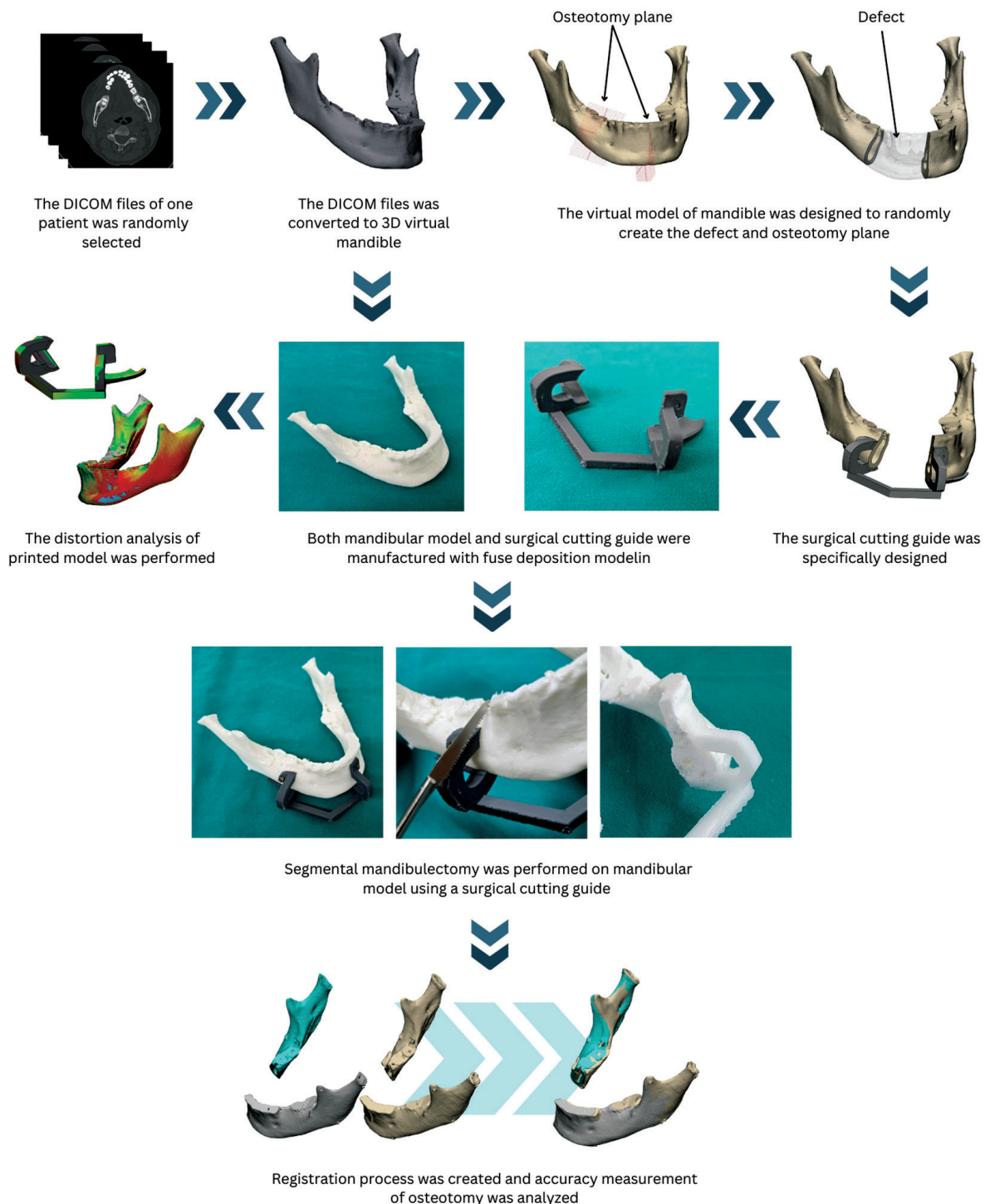


Figure 1: Study workflow of surgical simulation and personalized surgical cutting guide.

Surgical simulation and stereolithography manufacturing

The study workflow is presented in Figure 1. An image dataset of one patient with normal mandible morphology was randomly selected from the patients who obtained CBCT images involving the mandible using ORTHOPHOS XG 3D (Dentsply Sirona, New York, NY, USA) at 84 kV, 10 mA, and a 0.16-mm slice thickness. The CBCT images were exported in a Digital Imaging and Communications in Medicine (DICOM) format and imported into Mimics Research software V.20 (Materialise, Leuven, Belgium) to generate a three-dimensional (3D) virtual model of the mandible. Subsequently, the 3D virtual model was exported in Standard Triangle Language (STL) format to 3-Matic Medical software V.12 (Materialise, Leuven, Belgium). An observer indicated fiducial marks at the most lateral part of the condylar head and the angle of the mandible. Twenty 3D virtual models of mandibular stereolithography with fiducial marks and fuse deposition modeling (FDM) were manufactured using a Flashforge adventure-3 printer (Flashforge, ZheJiang, China).

A surgical simulation of segmental mandibulectomy was established on the 3D virtual mandibular model of the same patient. The planned segmental mandibulecto-

my model (planned SM model) was randomly cut at two different positions to create 20 mandibular defects (40 osteotomy planes) according to HCL classification⁽⁵⁾: two C defects, eight L defects, eight LC defects, and two LCL defects. This process was independently performed by one researcher. Using the STL file of these designs, the surgical cutting guides were printed with FDM using a Flashforge adventure-3 printer (Flashforge, ZheJiang, China).

Segmental mandibulectomy procedure

All segmental mandibulectomy procedures were performed on the mandibular stereolithography by one oral and maxillofacial surgeon. The surgical cutting guide was secured to the mandibular stereolithography using miniscrews, and the osteotomy was performed using a reciprocating saw (Sciencemedic Gyeonggi-do, South Korea). Following segmental mandibulectomy procedures, the remaining parts of the mandibular stereolithography were scanned using a CS 9600 CBCT scanner (Carestream Dental LLC, GA, USA) at 91 kVP, 2 mA, and 0.30-mm slice thicknesses. The obtained DICOM files were converted to a 3D virtual model (Post-SM model) in Mimics Research software V.20 (Materialise, Leuven, Belgium).

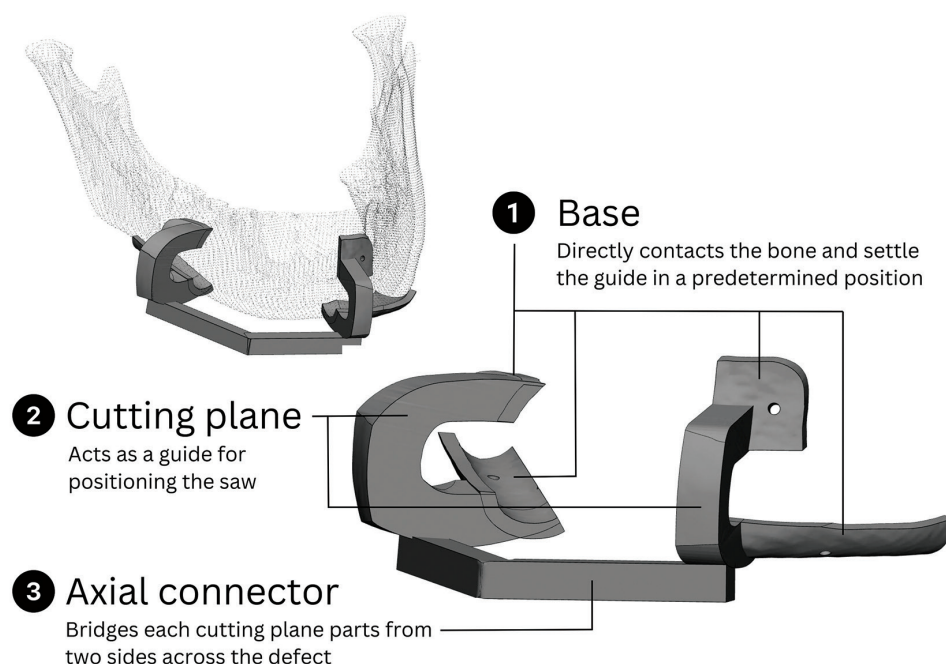


Figure 2: Diagram of virtual design of a three-dimensional model and an in-house personalized surgical cutting guide for mandibular reconstruction with nonvascularized iliac bone graft, with descriptions of each component.

Registration process and accuracy measurement of osteotomy

Using 3-Matic Medical software V.12 (Materialise, Leuven, Belgium), the post-SM model was superimposed onto the planned SM model and registered based on the remaining condyle-angle complex with fiducial marks. The osteotomy plane was created by defining three selected points on the cutting cross-sectional area, and the center points of each osteotomy plane were located. The osteotomy plane located distally to the defect was defined as the distal osteotomy plane, and those located medially to the defect were defined as the medial osteotomy plane. For type C defects, the osteotomy plane located on the left side of the defect referred to the medial osteotomy plane, and the contralateral side referred to the distal osteotomy plane. The angle formed by the osteotomy plane between the post-SM model and the planned SM model was the angulation deviation of osteotomy, and the distance deviation of the osteotomy plane was the distance between the center points.

The distortion of the surgical cutting guide and mandible model was also evaluated. All printed surgical cutting guides and mandible models were scanned using a cs 9600 CBCT scanner (Carestream Dental LLC, GA, USA) at 91 kVP, 2mA, and 0.30-mm slice thicknesses and converted to a 3D virtual model (actual guide model) in Mimics Research software V.20 (Materialise, Leuven, Belgium). The printed model was superimposed onto the virtual model using the Global Registration function, which allows to modify the distance threshold, the number of iterations and the subsample ratio to ensure maximum possible superimposition. After superimposition, a part comparison analysis was applied. The distortion of

the surgical cutting guide and mandible models refers to the absolute distance deviation between the actual guide model and virtual guide model and the root mean square (RMS) value, automatically calculated within the software. All measurements were performed by one researcher. The accuracy measurement is presented in Figure 3.

Statistical analysis

The sample size and statistical analyses were calculated using Stata statistical software, release 17 (College Station, TX, USA: StataCorp LLC), based on a previous study⁽⁶⁾, which reported that the mean deviation of the cutting plane was 0.2 ± 0.3 degree with a considered 95% confidence interval (CI) and 80% test power. Consequently, the minimum sample size result was 20 cutting planes.

Before conducting the study, the reliability of the accuracy measurement was determined by ensuring that the intraclass correlation coefficient (ICC)⁽⁷⁾ was equal to or greater than 0.75. All accuracy measurements were taken twice, one week apart, to maximize reliability. The average between the two values was chosen as a representative value. The absolute angulation and distance deviation of osteotomy were presented as mean, standard deviation (SD), and 95% CI. A boxplot was used to visualize the range of values covered by the data and any outliers.

Results

Regarding the distortion analysis, the absolute distance deviation of the surgical cutting guides was -0.3306 ± 0.0565 mm, and the RMS was 0.8183 ± 0.0255 mm for the entire guide surface. The absolute distance deviation of the mandible models was -0.2458 ± 0.0522

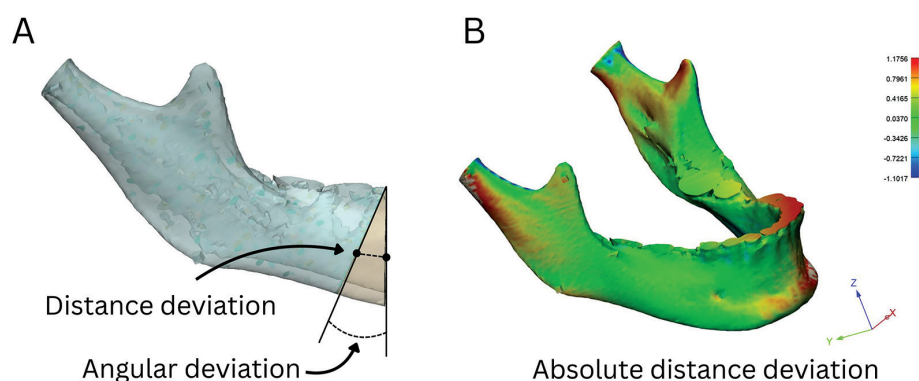


Figure 3: Error measurement between virtual and actual osteotomy in software using angular and distance deviation (A) and distortion analysis of model using absolute distance deviation (B).

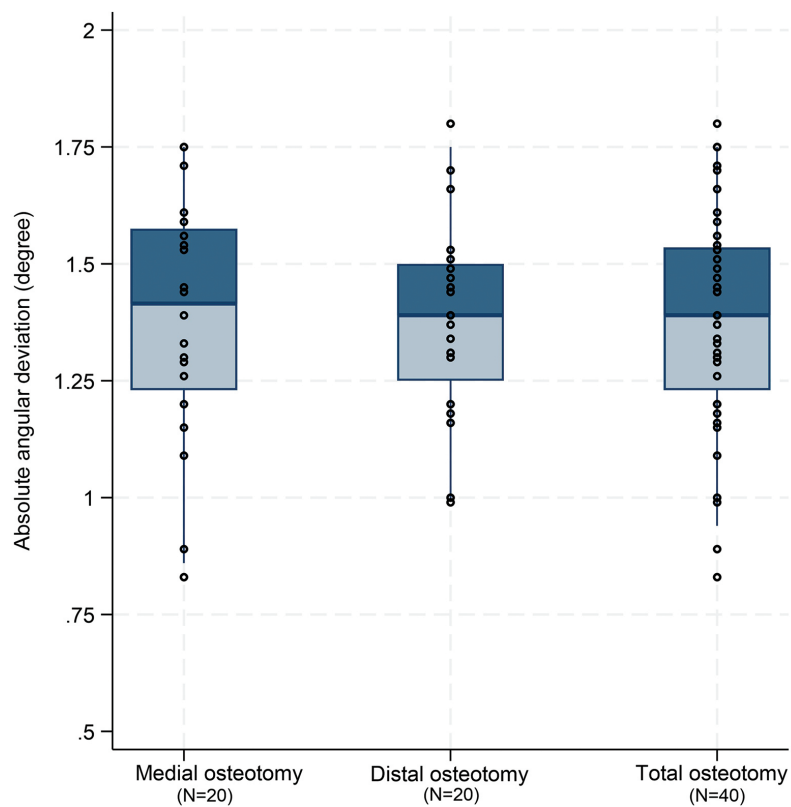


Figure 4: Angular deviation of osteotomy between virtual and actual osteotomy in model.

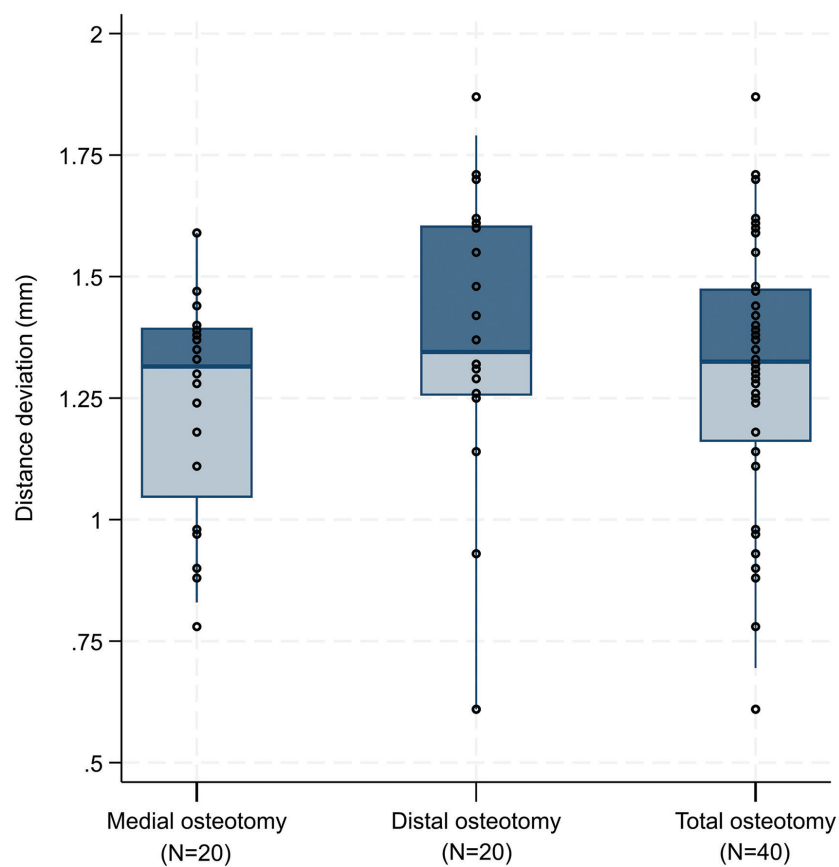


Figure 5: Distance deviation of osteotomy between virtual and actual osteotomy in model.

Table 1: Error in segmental mandibulectomy osteotomy.

No.	Type of defect*	Angular deviation (°)		Distance deviation (mm)	
		Medial osteotomy plane	Distal osteotomy plane	Medial osteotomy plane	Distal osteotomy plane
1	C	1.44	1.70	1.59	1.62
2	L	1.29	1.31	1.28	1.25
3	L	1.71	1.20	1.24	1.70
4	L	1.26	1.16	1.47	1.31
5	LC	1.39	0.99	0.88	1.42
6	L	1.33	1.30	1.39	1.60
7	LC	1.15	1.39	1.33	1.55
8	C	0.89	1.47	0.97	1.29
9	LC	1.75	1.53	0.98	0.61
10	LC	1.54	1.80	1.37	1.37
11	LC	1.59	1.49	1.35	1.87
12	LCL	1.56	1.51	1.18	1.48
13	LC	1.09	1.39	1.40	1.32
14	LCL	1.45	1.37	1.30	1.26
15	L	1.53	1.45	1.59	1.32
16	L	1.30	1.18	1.11	1.14
17	LC	1.61	1.34	1.44	1.61
18	L	1.75	1.44	1.38	0.61
19	L	0.83	1.00	0.78	0.93
20	LC	1.20	1.66	0.90	1.71
Average (mean ± SD)		1.38±0.26	1.36±0.22	1.27±0.23	1.35±0.33
Total (mean ± SD)		1.3835±0.2357 [95% CI; 1.3081-1.4588]		1.2975±0.2907 [95% CI; 1.2045-1.3904]	

Abbreviations: SD, standard deviation; mm, millimeters; CI, confident interval

*according to HCL classification by Boyd and colleagues (1993).

mm, and the RMS was 1.0453 ± 0.0100 mm. The deviation of osteotomy using the in-house surgical cutting guide is shown in Table 1. The mean absolute angulation deviation of osteotomy (Figure 4) was 1.3835 ± 0.2357 degree (95% CI: 1.3081-1.4588 degree), and the mean absolute distance deviation of osteotomy (Figure 5) was 1.2975 ± 0.2907 mm (95% CI: 1.2045-1.3904 mm).

Discussion

Precise osteotomy is crucial for successful ablative surgery in patients with benign or malignant intraosseous tumors and for reducing local tumor recurrence. This ensures the complete removal of the tumor while preserving as much healthy tissue as possible, which is critical for maintaining the structural integrity and aesthetic appearance of the head and neck region. The application of CASs, such as virtual surgical planning, patient-specific

cutting guides, and surgical navigation, has significantly enhanced the accuracy of osteotomy in surgery. Previous studies have shown that precise osteotomies with patient-specific cutting guides contributed to better surgical outcomes in terms of enhanced bony union, reduced operative time, and fewer complications when compared to the conventional freehand technique.⁽⁸⁻¹⁰⁾

When performing a segmental mandibulectomy using conventional techniques, maxillomandibular fixation was typically performed to maintain condylar position and occlusion after the continuity defect was created. Most novel CASs for the segmental mandibulectomy procedure typically help obtain precise surgical margins and eliminate the need for maxillomandibular fixation by using surgical cutting guides combined with customized titanium plates. However, using customized titanium plates incurs additional costs. Therefore, this CAS work-

flow has designed a surgical cutting guide that holds both segments together after osteotomy without the need for customized plates. The development of in-house surgical cutting guides for mandibular reconstruction offers several advantages, especially cost-effectiveness and faster production times. One challenge is proving the precision and validation of these in-house surgical cutting guides to ensure consistent and reliable outcomes.⁽¹¹⁾ Several studies have highlighted the role of CAS in mandibular reconstruction using vascularized bone grafts, especially vascularized fibula grafts or vascularized iliac bone grafts. Numajiri *et al.*, developed low-cost surgical cutting guides for mandibular reconstruction with free fibular flaps and found that the error of the osteotomy plan was 0.66 mm for mandibular osteotomies and 0.92 mm for fibular osteotomies.⁽¹²⁾ Lim *et al.*, also revealed that the average error of mandibular osteotomies was 1.1 ± 0.6 mm when using printed cutting guides.⁽¹³⁾ Recently, the navigated cutting guide system has been introduced, with the benefit of flexibility during surgery. Ter Braak *et al.*,⁽¹⁴⁾ evaluated the accuracy of this navigated cutting guide and found that the error in distance was 1.1 ± 0.6 mm, the error in yaw was 1.8 ± 1.4 degree, and the error in roll was 1.6 ± 1.3 degree.

This *in vitro* study validated the feasible performance of osteotomy using an in-house surgical cutting guide for partial mandibulectomy. This guide design had a mean angulation deviation (error) of 1.3835 degree and a mean distance deviation (error) of 1.2975 mm for osteotomy. The inaccuracies of CAS are caused by errors that occur during the processes of data acquisition, computer-assisted design, computer-assisted manufacturing, transfer to actual surgery, and postoperative evaluation. Van Baar *et al.*, performed a systematic review and identified a variety of CAS planning approaches, ranging from data acquisition to postoperative evaluation. The ability to compare accuracy measurements in CAS was thus limited.⁽¹⁵⁾ The clinically acceptable error for the osteotomy plane when using surgical cutting guides in mandibular reconstruction generally ranges from 1 to 3 mm, with 2 to 5 degree for angular deviations.^(14,16) Thus, this proof-of-concept study showed that our in-house surgical cutting guide was not inferior to those reported in previous studies, achieving osteotomy planes with clinically acceptable values.

Some concerns remain that require clarification. First, as in previous studies using stereolithography mod-

els, the printed mandibular models could not be perfectly cut due to the plasticity of the material used. The error at the osteotomy plane might be greater than the error produced in clinical settings when the osteotomy is performed on real bone. Second, the approach to positioning the surgical cutting guide in a predetermined position and performing the osteotomy was straightforward, without any interference from other tissues as would occur in actual surgery. Future clinical studies are needed to confirm the precision. Third, the distortion of the printed mandibular models and surgical cutting guides also affects osteotomy deviations. The literature indicates that acceptable discrepancies between 3D printed medical models and reference data or RMS typically do not exceed 1 mm.⁽¹⁷⁾ Thus, the distortion was acceptable in this present study; hence, it is unlikely to confound the error measurement. Fourth, the questionable rigidity of the surgical cutting guide could confound the accuracy of the second osteotomy. Since the surgical cutting guide's body must be sufficiently thin to provide visibility of the surgical field while maintaining adequate rigidity and stability, defining the optimal size of the surgical cutting guide that is clinically acceptable in this *in vitro* study is difficult. Lastly, when the mandibular model was cut manually, the errors of the surgical technique depended on the surgeon's skill and perspective. To minimize this bias, all surgical procedures in this study were performed by a single expert surgeon.

Further improvements are planned to this in-house surgical cutting guide. Essentially, the surgical cutting guide should be rigid enough to stably bridge and secure the remaining parts of the mandible. The optimal size of the axial connector will be investigated and refined in future clinical studies to ensure rigidity. An effective surgical cutting guide should produce precise osteotomy regardless of the surgeon's expertise. Future studies should evaluate the effectiveness across a diverse group of surgeons with varying levels of experience. Additionally, the accuracy, clinical feasibility, relevant clinical outcomes, and cost-effectiveness will be investigated in clinical settings. Such research will provide valuable insights into the applicability of this in-house surgical cutting guide and assist in refining its design and implementation. Thus, it will aid in developing more reliable surgical cutting guides for segmental mandibulectomy and iliac bone harvesting, ensuring precise surgical margins and accurate acquisition of bone volume for grafting the defect.

Conclusions

This *in vitro* study validated the feasibility of a surgical cutting guide design. This in-house personalized surgical cutting guide for segmental mandibulectomy, which is the component of in-house CAS workflow, facilitated the precise and reproducible osteotomy on the mandible before mandibular reconstruction, with clinically acceptable values. Further investigations in actual surgery are necessary to ensure clinical benefits.

Acknowledgments

The authors would like to extend their deepest gratitude to the dedicated dental staff at the Oral and Maxillofacial Radiology Clinic, Faculty of Dentistry, Chiang Mai University for their invaluable assistance and unwavering support. This study was supported by The Royal College of Dental Surgeons of Thailand.

Conflicts of Interest

The authors declare that they hold no competing interests.

References

1. Bagheri SC, Bell RB, Khan HA. Current therapy in oral and maxillofacial surgery. Philadelphia: Elsevier Saunders; 2012.
2. Kumar BP, Venkatesh V, Kumar KA, Yadav BY, Mohan SR. Mandibular reconstruction: overview. J Maxillofac Oral Surg. 2016;15(4):425-41.
3. Powcharoen W, Yang WF, Yan Li K, Zhu W, Su YX. Computer-assisted versus conventional freehand mandibular reconstruction with fibula free flap: a systematic review and meta-analysis. Plast Reconstr Surg. 2019;144(6):1417-28.
4. Yang WF, Choi WS, Wong MC, Powcharoen W, Zhu WY, Tsoi JK, *et al.* Three-dimensionally printed patient-specific surgical plates increase accuracy of oncologic head and neck reconstruction versus conventional surgical plates: a comparative study. Ann Surg Oncol. 2021;28(1):363-75.
5. Boyd JB, Gullane PJ, Rotstein LE, Brown DH, Irish JC. Classification of mandibular defects. Plast Reconstr Surg. 1993;92(7):1266-75.
6. Donnez M, Ollivier M, Munier M, Berton P, Podgorski JP, Chabrand P, *et al.* Are three-dimensional patient-specific cutting guides for open wedge high tibial osteotomy accurate? an *in vitro* study. J Orthop Surg Res. 2018;13(1):171.
7. Koo TK, Li MY. A Guideline of selecting and reporting intraclass correlation coefficients for reliability research. J Chiropr Med. 2016;15(2):155-63.
8. May MM, Howe BM, O'Byrne TJ, Alexander AE, Morris JM, Moore EJ, *et al.* Short and long-term outcomes of three-dimensional printed surgical guides and virtual surgical planning versus conventional methods for fibula free flap reconstruction of the mandible: decreased nonunion and complication rates. Head Neck. 2021;43(8):2342-52.
9. Bouchet B, Raoul G, Julieron B, Wojcik T. Functional and morphologic outcomes of CAD/CAM-assisted versus conventional microvascular fibular free flap reconstruction of the mandible: a retrospective study of 25 cases. J Stomatol Oral Maxillofac Surg. 2018;119(6):455-60.
10. Dalband M, Badkoobeh A, Alam M, Motie P, Tabrizi R. Comparison of the outcome of free iliac bone graft and vascularized iliac bone graft in reconstruction of mandibular defects: a systematic review. J Maxillofac Oral Surg. 2024;23(6):1371-8.
11. Sun Q, Zhu Z, Meng F, Zhao R, Li X, Long X, *et al.* Application of a modified osteotomy and positioning integrative template system (MOPITS) based on a truncatable reconstruction model in the precise mandibular reconstruction with fibula free flap: a pilot clinical study. BMC Oral Health. 2023;23(1):842.
12. Numajiri T, Nakamura H, Sowa Y, Nishino K. Low-cost design and manufacturing of surgical guides for mandibular reconstruction using a fibula. Plast Reconstr Surg Glob Open. 2016;4(7):e805.
13. Lim SH, Kim MK, Kang SH. Precision of fibula positioning guide in mandibular reconstruction with a fibula graft. Head Face Med. 2016;12:7. doi: 10.1186/s13005-016-0104-2.
14. Ter Braak TP, Brouwer de Koning SG, van Alphen MJA, van der Heijden F, Schreuder WH, van Veen RLP, *et al.* A surgical navigated cutting guide for mandibular osteotomies: accuracy and reproducibility of an image-guided mandibular osteotomy. Int J Comput Ass Rad. 2020;15(10):1719-25.
15. Van Baar GJC, Forouzanfar T, Liberton N, Winters HAH, Leusink FKJ. Accuracy of computer-assisted surgery in mandibular reconstruction: a systematic review. Oral Oncol. 2018;84:52-60.
16. Bernstein JM, Daly MJ, Chan H, Qiu J, Goldstein D, Muhanna N, *et al.* Accuracy and reproducibility of virtual cutting guides and 3D-navigation for osteotomies of the mandible and maxilla. PLoS One. 2017;12(3):e0173111.
17. George E, Liacouras P, Rybicki FJ, Mitsouras D. Measuring and establishing the accuracy and reproducibility of 3D printed medical models. Radiographics. 2017;37:1424-50.