



Editor:
Pinpinut Wanichsaihong,
Chiang Mai University, Thailand.

Received: March 2, 2022
Revised: September 30, 2022
Accepted: October 31, 2022

Corresponding Author:
Associate Professor
Orapin Komin,
Department of Prosthodontics,
Faculty of Dentistry, Chulalongkorn
University, Bangkok 10330, Thailand.
E-mail: Orapin.geriatric@gmail.com

Case Report: Prosthesis (Complete Denture) for Communication and Behavioral Impaired Dementia Patient

Patcharaporn Gavila^{1,2}, Orapin Komin³

¹Intercountry Centre for Oral Health, Department of Health, Ministry of Public Health, Thailand.

²Master's Degree Student of Geriatric Dentistry and Special Patients Care (International program), Faculty of Dentistry, Chulalongkorn University, Thailand.

³Department of Prosthodontics, Faculty of Dentistry, Chulalongkorn University, Thailand.

Abstract

Aim: To describe the procedures for complete denture fabrication in dementia and behavioral impairment patient and how to manage the case holistically.

Methods and Results: The patient was a 77-year-old woman diagnosed with moderate dementia, Alzheimer's disease with Behavioral and Psychological Symptoms of Dementia. The patient lost her previous complete dentures. She had signs of agnosia, communication problems and behavioral control. These aspects increased the difficulty in her daily life activities and in providing dental treatment. Our goal was to restore her oral function and to improve her overall general health by fabricating new complete dentures. An online consultation was used to oversee the behavioral management, adaptation in posture, and techniques in prosthodontic procedures between the postgraduate dental student providing this treatment and the prosthodontic specialist in an academic institute while they were in different places. The dental treatment in this case was provided holistically and patient-centered, the dental treatment outcomes were achieved through the follow-up visits.

Conclusions: This case study revealed that a dementia patient could receive appropriate dental treatment in cooperation with the care team to maintain her oral health function. Behavioral management could be performed using non-pharmacological methods. After delivering the denture, the patient's nutritional status and the quality of life largely depends on the caregiver when the dementia progresses.

Keywords: Alzheimer's disease, behavioral management, caregivers, complete denture, holistic health

Introduction

Alzheimer's disease (AD) is a progressive neurodegenerative brain disorder responsible for 60-80% of dementia cases in elderly people.⁽¹⁾ The clinical characteristics of dementia typically begin with subtle/poorly recognized memory failure (Mild Cognitive Impairment or MCI), slowly become more severe, and eventually incapacitating.⁽²⁾ Most individuals with dementia experience progressive cognitive decline and non-cognitive symptoms, such as various Behavioral and Psychological Symptoms of Dementia (BPSD). BPSD comprises many symptoms that may be expressed at all dementia stages. Agitation, apathy, altered sleep patterns, depressive behavior, and aberrant motor behavior are examples of BPSD.⁽³⁾ Worldwide, females are more prone to AD than males, and the risk increases with age.⁽⁴⁾ The more severe the stage, the greater the dependency level in AD patients. This can cause stress and psychological morbidity in caregivers; behavioral symptoms and impairment in daily living activities in AD patients are associated with caregiver stress.⁽⁵⁾ The main causes of death of an AD patient are general infection, malnutrition, pneumonia, or dehydration.⁽⁶⁾

The dental treatments for moderate to severe stage dementia patients are difficult to perform due to the progressive cognitive decline that alters their cooperation and behavior while receiving dental procedures. Although the decision making in providing prosthodontic dental treatment to dementia patients is challenging, the patient's oral health-related quality of life needs to be considered because there are many psychosocial aspects that contribute to it. When appropriate dental management increases the patient's quality of life as best that it can, it is important to maintain the oral health function until the end stage of dementia occurs.

Materials and Methods

A 77-year-old Australian female diagnosed as AD with BPSD by an Australian psychologist, was referred from an adult care facility to the Intercountry Centre for Oral Health (ICOH) dental clinic in Chiangmai for a new denture. The totally edentulous patient had lost her previous complete denture approximately 5 months prior to her visit. In 2016 when she was diagnosed with early onset of dementia Alzheimer's type, her family took care of her until the dementia symptoms declined and the

family could not provide her the appropriate care. Her family decided to move her to the care resident in Chiang Mai, Thailand for appropriate long-term stay in 2017.

The first few years as an in care resident, the patient lived alone in a house located on the grounds of the care facility. She did not require full time nursing care and did not have a specific caregiver but shared one with other residents. The caregivers at the facility are registered nurses. They provided care for each resident according to their Activity of Daily Living (ADL) score. The patient in this report required major assistance for complex tasking or the IADL (Instrumental Activity of Daily Living), such as making a phone call, playing a board game, doing exercises, or going out of the care residence, however she could perform other ADL, such as showering, dressing, eating, and walking, by herself. Furthermore, she could wear and take care of her old dentures by herself without any complaint. She usually took the dentures out at night and placed them in a glass of water in her bathroom, while the nurses found many dental adhesive tubes around her house.

In May 2020, a nurse noticed that she was eating without her dentures. However, the patient was not aware of this problem. In addition, the patient did not eat or drink during the daytime. Therefore, after she lost her dentures, her body weight decreased by 5 kilograms over five months. Her face and body appeared to be neglected as her symptoms of dementia progressed. Her family and caregiver were concerned about her health and nutritional status, thus, they sought dental treatment to fabricate new dentures for the patient. In addition to her physical health, when she did not have her denture, her mental health and quality of life were also reduced.

Due to the patient's uncontrolled and aggressive behavior, we needed a well-designed treatment plan. The patient's care was provided by one of the authors (PG) under the direction of the Geriatric Dentistry and Special Patient Care program, Faculty of Dentistry, Chulalongkorn University. After gathering the patient's history and performing her examination, we used an online platform via text/picture/video chat messages and real-time VDO calls for consulting and discussing this case. Thus, real-time consultation during treatment was used to provide the appropriate management and the outcome was reviewed while we were in different locations.

At the first dental visit, the patient came to the ICOH dental clinic with a young nurse assistant who was not fluent in English. The patient appeared moody and frustrated about visiting the clinic. Her appearance and clothes were neglected. (Figure 1) We performed an oral examination and observed the patient's behavior and communication skills. Because her main caregiver did not accompany her, the patient's history was taken by interviewing the caregiver by phone call on the first visit. Based on the patient's comprehension and behavior, we requested the main caregiver to come with the patient for the subsequent dental visits.



Figure 1: On the first dental visit the patient was moody and frustrated. Her appearance and clothes were neglected.

The extraoral examination revealed that the patient had an ovoid facial shape with a slightly concave lateral facial profile. The temporomandibular joint examination indicated no significant pathological deviation. The intra-oral examination revealed high and well-rounded totally edentulous maxillary and mandibular ridges. There was no sign of infection or inflammation in the oral cavity. The tongue and oral mucosa were clean and moist.

Due to her AD symptoms, she was confused and disoriented. Her past medical history comprised hypertension, osteoarthritis of the neck and spine, clavicular fractures, and pancreatitis. Her only current medication was Seroquel XR, an antipsychotic medicine, 50 mg, ½ tab at breakfast and 1 tab at bedtime. Her Barthel Activity of Daily Living (ADL) score was 12, which indicated a totally dependent status. Her Mini Mental State Examination (MMSE)⁽⁷⁾ score was 11-13 out of 30, defined

as moderately cognitive impairment. We evaluated her clinical frailty as moderately frail⁽⁸⁾; although she could walk without a cane or wheelchair, she needed assistance for all outside activities. Considering her behavioral and psychological symptoms, she had a history of aggressive behavior, mood swings, depression and sleep disturbance at night.

The patient had difficulty in speaking when we asked her questions; she had delayed responses and could not understand long or complex questions. Her responses were brief and repetitive. Sometimes she refused to follow the requests or orders and would not cooperate during simple procedures, such as taking the preliminary impression, which is a critical procedure for fabricating a complete denture.

The dental treatment plan was discussed with her main caregiver and the family abroad. The final decision was made after we evaluated the patient and discussed the case online. The main caregiver, who was a registered nurse and was fluent in English accompanied her for her dental treatment in the subsequent visits.

On the second visit the upper arch preliminary impression was performed. The patient could not tolerate the alginate impression material texture. She had a severe gag reflex when we delivered the tray with impression material into her mouth. Furthermore, she pulled the tray and material out before it set. On the third and fourth visit, we positioned the patient to sit on the dental bed to reduce the gag reflex, then used fast-set alginate with warm water to reduce the setting time. Managing her behavior and moods using a clear voice tone, eye contact, and gentle hand-restraining by her caregiver and a dental assistant helped the patient calm down and be more cooperative. Using these methods, we obtained an appropriately detailed impression; the upper arch impression had some defects in the tuberosity and anterior portion, while the lower arch impression had good detail. We used this impression for the master model. (Figure 2)

We had difficulty trying in the upper arch occlusion rim. The patient experienced the gag reflex soon after we placed it in her mouth. Therefore, the posterior border of the upper arch acrylic rim was shortened before try in. (Figure 3)

After the modification, the patient cooperated throughout the procedure. The level and contour of the bite block were measured, the midline and canine line were

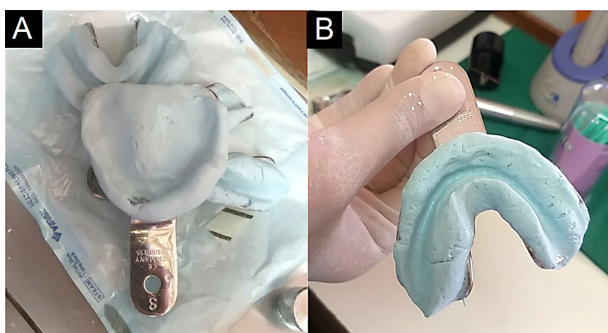


Figure 2: The preliminary impression that we use as the final impression. The upper arch (2A) and the lower arch (2B).

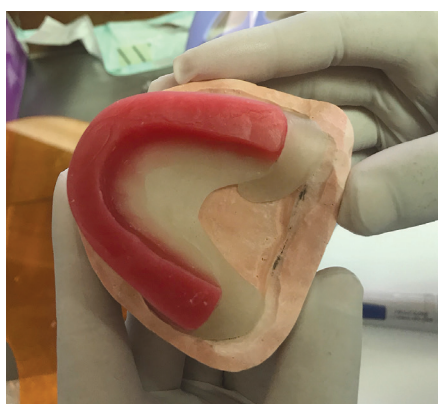

Figure 3: We shortened the posterior border of the upper arch occlusal rim for the try in.

marked. Subsequently, wax bite registration material was used for recording the jaw relation. The patient was asked to watch and follow the dentist. The vertical dimension was determined until it reached the appropriate height. The denture teeth were arranged using non-anatomic teeth to reduce lateral interference. The esthetic try-in and jaw relation verification was done using a trial denture. Due to the midline shift, the jaw relation record was re-verified with vinylpolysiloxane bite registration (Blu-moose[®], parkell[®], Edgewood, NY, USA) to consume lesser time. The upper denture palate portion was waxed up to regain full palate coverage. Both dentures were fabricated using high impact resin. Although the upper denture was slightly loose, the lower denture had good retention and stability. The tissue surface and denture border were evaluated with pressure-indicating paste (Keystone, Gibbstown, NJ, USA). Occlusal correction was performed intraorally to eliminate occlusal interferences.

Denture cleansing tablets were prescribed to improve the denture's hygiene. The importance of

prosthesis hygiene and removing the prosthesis at bedtime was emphasized to the caregiver. The patient was appointed for follow-up visits to evaluate and adjust the denture as needed. The summary of the treatment processes, the problem list, and the solution strategy are shown in Table 1.

Results

After delivering the dentures, the patient could wear the dentures and remove them by herself. However, the patient hesitated to wear the dentures, especially the upper denture because it was slightly loose and stimulated her gag reflex. During the occlusal adjustments, we used a temporary dental adhesive to make the denture stable in her mouth. After two weeks, the patient adapted herself to the new dentures. We subsequently applied Dynamic Impression Lining material (DIL: KAMEMIZU[®], Osaka, Japan) on the upper denture border that acted as the functional impression material, which began auto-curing 3-5 d after lining. This step helped the patient to become more comfortable with her denture, while improving the denture retention and stability.

The caregiver was the key person who supported the patient to wear the denture. One month after denture delivery, the patient refused to wear the dentures all the time except at mealtimes. Due to the worsening of her AD symptoms, she required a private nurse 8 h. a day. The denture together with encouragement from the caregiver improve the quantity and quality of the meals and she gained 4 kg after 3 months. Her appearance and mood also greatly improved. (Figure 4)

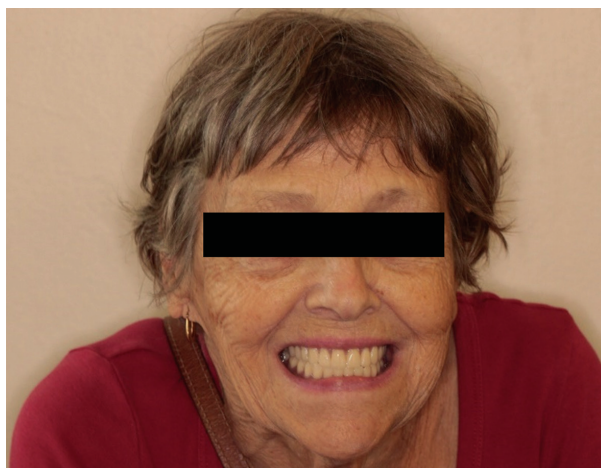

Figure 4: The patient at the 1-month recall.

Table 1: The workflow of the treatment processes, the problem list, and the solution strategies.

Visit	Duration	Clinical treatment	Problems list	Solving strategies
1	90 mins	- History taking - Extra-intraoral examination	- Patient could not retrieve self-information - Uncooperative behavior	- Interviewed the keyperson which is the main caregiver who responsible to the care of patient - Cooperated with the specific caregiver who can manage patient's behavior - Prepared the dental clinic environment to be quiet, calm and pleasant
2	45 mins	Take 1 st preliminary impression	Uncooperative behavior: pull the impression tray out before the impression material were set due to high gag reflex	- Scheduled the dental treatment to coincide with regularly scheduled antipsychotics drug or morning schedule within 2-3 hours after wakeup - Short-visit appointment - Fast-set impression material and warm temperature water - Behavioral management: non-verbal communication; eye contact and gentle touch - Adjusted patient to upright position during procedure - Cooperated with the main caregiver and dental assistant to distract patient while waiting the impression to set - Desensitized with hand pumping in the impression material prior the dental impression
3	45 mins	Take 2 nd preliminary impression		
4	45 mins	Take 3 rd preliminary impression		
5	45 mins	Try in occlusion rim	The distal part of palatal plate of upper occlusal rim provokes the gag-reflex.	- Cut the distal part on upper of occlusion rim in horse-shoe shape
6-7	60 mins	Verified vertical dimension	Patient could not bite in the same position.	- Trained the patient to bite by tell-show-do technique and repeated it over - Short intervals visit between 6 th and 7 th visit
8	60 mins	Try in teeth	The baseplates are loose.	- Used the temporary dental adhesive
9	45 mins	Denture delivery	- The upper denture got loose - Patient could wear dentures for a period and took it off by herself.	- Used the temporary dental adhesive for making it stable in the mouth for occlusal adjustment - Convinced patient to wear denture and emphasized the main caregiver to supervise and checking the oral mucosa if there was any redness or ulcer before seeing the dentist in next visit
10	30 mins	Recheck 1 week	Could not retrieve signs and symptoms for adaptation after denture delivery because patient refuse to wear denture.	- Emphasized the caregiver to supervise the patient to wear denture at mealtime and collect patient's symptoms after denture were used by interviewing the main caregiver
11	45 mins	Recheck 2 weeks	The upper denture got loose.	- Used DIL for relining material
12	45 mins	Recheck 1 month	DIL got hardening and had porosis tend to get denture stomatitis.	- Adjusted tissue surface of denture to remove porous and spicules - Emphasized OHI to the caregiver

Discussion

Most individuals with dementia suffer progressive cognitive decline and non-cognitive symptoms, such as behavioral changes.^(3,9) Therefore, simple dental procedures cannot be performed easily due to the patient's confusion, disorientation, and mood changes. Non-pharmacological interventions were used in this case rather than medication or sedation due to their side effects, such as increased confusion, increased fall risk, drowsiness, and dizziness.⁽¹⁰⁾

A caregiver with good communication skill plays an important role in receiving dental treatment and daily life activities for the patient. Good communication, including explaining in detail with simple words about the dental procedures, can reduce the patient's confusion while gaining trust during the process. According to the House Mental Classification System of Denture Patients,⁽¹¹⁾ the patient and/or their family factor are the importance factors that need to be evaluated before providing the treatment.

The main position of the patient during the procedures was upright on the dental bed. For the occlusion recorded, wax bite registration material was used due to its accuracy and reusability.⁽¹²⁾ Blu-Mousse[®], which is fast-setting and user friendly, is also the material of choice despite its price for dementia patients who experience disorientation and restlessness. The zero-degree artificial teeth were used to avoid lateral interference.⁽¹³⁾

DIL, composed of chemically-cured poly (ethyl-methacrylate) and polyfunctional methacrylate, was used to improve the retention of the upper denture.⁽¹⁴⁾ After mixing and placed intraorally, the DIL gradually adjust itself to the shape of the edentulous ridge and mucosa, then fully polymerizes after one week. The DIL was used as a long-term permanent material that should be replaced every 6 months.

In this case we used behavior management and communication strategies by always approaching the patient from the front. A person who is familiar with the patient, or the patient trusts should always be present during the treatment sessions. The dentist used short and simple words when talking to the patient. A slow, clear, and low voice tone was used. Sometimes the sentences or instructions were repeated and we waited for the patient's response. Eye contact, smiling, and gentle touches raised the trust between the dental personal and the patient. The empathy

that the clinician and other dental personals showed to the patient markedly improve the patient's trust. Non-verbal communication, i.e., body language, was very important, the patient could better perceive intension non-verbally.⁽¹⁴⁾ Uncooperativeness can occur during a dental procedure because of patient mistrust and the unfamiliar environment. A quiet dental clinic environment and music therapy can create calm and positive behavior in dementia patients.⁽¹²⁾

Our clinical observations revealed that the patient adapted to the new denture more easily than we expected. Her past denture experience might have shortened the adaptation period, also she had not gone long without her dentures. A previous study found that there was a significant correlation between the ability to wear and remove the denture and the ADL score and the dementia severity level, however, age was not correlated with this ability.⁽¹³⁻¹⁴⁾ The factors relating to denture wearing were being able to communicate, wear clothes, eat, wash, get up from a chair or bed, and the number of remaining teeth.⁽⁴⁾ Therefore, maintaining the ADL level is important.

The prosthodontic process for CD fabrication does not require too much patient cooperation, which allows for achieving a good outcome without invasive behavioral management. In contrast, if a dementia patient has some remaining teeth in their mouth, some procedures, such as tooth preparation, placing a restoration, water suctioning, or other steps that produce an unexpected sound or pain, this may trigger uncooperative and aggressive behavior. In that circumstance, medication or conscious/nonconscious sedation may provide the appropriate management rather than non-pharmacological methods.

When a patient's dementia condition worsens, the oral health related quality of life still needs to be considered because there are many psychosocial aspects to contemplate in addition to eating and nutrition, such as appearance and communication. Indeed, we continued to see these improvements during the follow-up visits. A prior study found that higher dependency rates in elderly individuals are correlated with the likelihood to receive less dental care.⁽⁴⁾ Therefore, we encourage this high dependency group to receive more appropriate oral care from a dental professional team or at least proper oral awareness and care from their caregiver.⁽¹⁵⁾

There should be dental service in elderly homes providing scheduled dental visits to the residentials.

Dental service in a familiar and relax environment elderly home will reduce the confusion and increase the positive behavior of dementia patients. The recall or maintenance service of oral health is also very important in older adults, especially for those in a high dependency group. Tele-medicine and teledentistry can contribute to the general and oral health of dependent patients by improving and continuing their medical and dental support. In addition, this tele-communication will reduce inequity in care access especially in frail people who cannot reach health services.

References

1. Korolev IO. Alzheimer's disease: a clinical and basic science review. *MSRJ*. 2014;4(1):24-33.
2. Bird TD. Alzheimer disease overview. *GeneReviews*[®] (Internet). 2018.
3. Bränsvik V, Granvik E, Minthon L, Nordström P, Nägga K. Mortality in patients with behavioural and psychological symptoms of dementia: a registry-based study. *Aging Ment Health*. 2020:1-9.
4. Barnes DE, Yaffe K. The projected effect of risk factor reduction on Alzheimer's disease prevalence. *Lancet Neurol*. 2011;10(9):819-28.
5. González-Salvador MT, Arango C, Lyketsos CG, Barba AC. The stress and psychological morbidity of the Alzheimer patient caregiver. *Int J Geriatr Psychiatry*. 1999;14(9):701-10.
6. Mahoney FI, Barthel DW. Functional evaluation: the barthel index. *Md State Med J*. 1965;14:61-5.
7. Rovner BW, Folstein MF. Mini-mental state exam in clinical practice. *Hosp Pract (Off Ed)*. 1987;22(1a):99-110.
8. Rockwood K, Fay S, Theou O, Dykes L. Clinical frailty scale. Halifax, NS: Geriatric Medicine Research, Dalhousie University. 2009.
9. Kocaelli H, Yaltirik M, Yargic LI, Özbas H. Alzheimer's disease and dental management. *Oral Surg Oral Med Oral Pathol Oral Radiol Endod*. 2002;93(5):521-4.
10. Fisher JE, Carstensen LL. Behavior management of the dementias. *Clinical Psychology Review*. 1990;10(6):611-29.
11. Winkler S. House mental classification system of denture patients: the contribution of Milus M. House. *J Oral Implantol*. 2005;31(6):301-3.
12. Critchlow SB, Ellis JS, Field JC. Reducing the risk of failure in complete denture patients. *Dent Update*. 2012;39(6):427-36.
13. Morita H, Hashimoto A, Inoue R, Yoshimoto S, Yoneda M, Hirofujii T. Successful fitting of a complete maxillary denture in a patient with severe Alzheimer's disease complicated by oral dyskinesia. *Case Rep Dent*. 2016;2016:4026480.
14. Chalmers JM. Behavior management and communication strategies for dental professionals when caring for patients with dementia. *Spec Care Dentist*. 2000;20(4):147-54.
15. McGrath C, Bedi R. The importance of oral health to older people's quality of life. *Gerodontology*. 1999;16(1):59-63.