

# Evaluation of Collagen Fibers in Hyperkeratosis and Different Types of Oral Epithelial Dysplasia by Using Picrosirius Red Staining

Rachai Juengsomjit<sup>1</sup>, Ounruean Meesakul<sup>1</sup>, Sorasun Rungsiyanont<sup>2</sup>

<sup>1</sup>Department of Oral and Maxillofacial Pathology, Faculty of Dentistry, Mahidol University, Thailand

<sup>2</sup>Department of Oral Surgery and Oral Medicine, Faculty of Dentistry, Srinakharinwirot University, Thailand

Received: August 6, 2021 • Revised: October 18, 2021 • Accepted: November 11, 2021

Corresponding Author: Associate Professor Dr. Sorasun Rungsiyanont, Department of Oral Surgery and Oral Medicine, Faculty of Dentistry, Srinakharinwirot University, Bangkok 10110 Thailand. (Email: [peted2000@hotmail.com](mailto:peted2000@hotmail.com))

## Abstract

Oral epithelial dysplasia (OED) is a sign of squamous cell carcinoma (SCC) progression. The dysplastic squamous epithelial cells degrade the stroma resulting in an invasion of the dysplastic epithelial cells into the underlying connective.

**Objectives:** We aim to evaluate collagen fibers by using picrosirius red staining among different types of epithelial dysplasia and their correlation to clinical parameters.

**Methods:** Eighty cases of paraffin blocks were retrieved and classified into 4 groups; hyperkeratosis, mild epithelial dysplasia, moderate epithelial dysplasia and severe epithelial dysplasia. Three cases of focal fibrous hyperplasia were used as positive controls. Picrosirius-red staining technique and investigating under a polarized light microscope were performed. The results were interpreted according to collagen fibers birefringence; (1) orange-red represents mature collagen patterns and (2) green-yellow represents the small diameter and immature collagen. (3) mixed birefringent rays of group (1) and (2).

**Results:** In hyperkeratosis cases, collagen fibers in most areas showed mixed orange-red to green-yellow similarly to collagen stained in mild epithelial dysplasia. However, in moderate to severe dysplasia, collagen fibers were generally stained in green-yellow. From clinical data, the average age of female samples was higher than that of male in all 3 types of epithelial dysplasia. The tongue was the most commonly affected site (32.5%) with homogeneous leukoplakia as the most common clinical feature (48.8%).

**Conclusions:** This present study reveals the relationship between the difference of the maturation of collagen fibers and histopathological diagnosis. The increase grade of OED represented in green-yellow birefringence refers to immature collagen.

**Keywords:** collagen fiber, epithelial dysplasia, picrosirius red staining

## Introduction

Oral epithelial dysplasia (OED) is characterized by the dysplastic changes in the stratified squamous epithelium layer. This histopathological change known as dysplasia is accepted as a sign that precede the progression to

squamous cell carcinoma (SCC).<sup>(1)</sup> The dysplastic squamous epithelial cells also degrade the stroma and resulting in the facilitation of the dysplastic epithelial cells invading into the underlying connective tissue. The World Health Organization (WHO) classification of head and neck

tumors in the year of 2017 classified diagnosis of epithelial dysplasia into mild, moderate, and severe dysplasia. For mild epithelial dysplasia, the abnormality confined in the lower one-third of the epithelial thickness. For moderate epithelial dysplasia, the abnormality involved between one-third and two-third of the epithelial thickness. If the dysplastic changes are shown in more than two-third of the epithelial thickness, it is severe epithelial dysplasia. From the most severe pattern so-called the carcinoma in situ or intra-epithelial carcinoma, the changes will be shown in the full thickness of the epithelium. The WHO classification notified that this grading system of this dysplasia has been accepted as a gold standard for the classification of epithelial dysplasia.<sup>(2)</sup> Higher grade dysplasia is one of the factors that increase the risk of malignant transformation in the premalignant lesion.

The stromal tissue consists of many components such as the extracellular matrix (ECM), growth factors, chemokines, cytokines, antibodies, metabolites, mesenchymal cells, cells of the vascular and immune systems. The interaction between the dysplastic squamous epithelial cells and ECM components were addressed. Since the collagen fibers are the main component of the ECM, the quality of the ECM depends on collagen content which play an important role in the process of tumor invasion and metastasis stages. At the period of the tumor progression, the changes of collagen fibers which are bundle diameter, color, type, density, and orientation were reported.<sup>(3)</sup> However, the connection between OED which accepted as the precursor lesion of SCC and collagen fibers is still unclear.

Picrosirius red (PSR) is an elongated dye that reacts with collagen fibers and promotes the enhancement of its normal birefringence when viewed under polarized light.<sup>(4)</sup> The birefringence colors of collagen fibers represent the thickness of the collagen fibers, the density of collagen fibers packing, and spatial arrangement.<sup>(5)</sup> Staining with PSR is widely used with its highly specific technique for evaluating collagen fibers and differentiating the different forms of collagen fibers. Moreover, this advantage of PSR can be applied to determine the alteration of collagen fibers function in the tumor progression. Another advantage of PSR is its staining stability. When compared with other special staining techniques such as trichrome stain, PSR staining seems to fade down slower and produces more specific stain for collagen. Moreover, PSR staining

can be used to analyze the maturity of collagen fibers.<sup>(6)</sup>

Many studies used PSR staining to detect and analyze collagen fiber changes in SCC. They found that in higher grades histopathological diagnosis of SCC and metastatic SCC cases, the birefringence reflected immature collagen.<sup>(7-9)</sup> At present, there are quite a few studies that focused on the oral potentially-malignant disorders by using the PSR staining to evaluate collagen fiber profiles.<sup>(10-12)</sup> For examples, Soma Susan Varghese's study<sup>(12)</sup> focused on OED and inflammatory fibrous hyperplasia. The study of Sharma *et al.* compared the collagen profiles between epithelial dysplasia and SCC.<sup>(11)</sup> Another study examined the collagen configuration in oral submucous fibrosis.<sup>(10)</sup>

The purpose of this study is to report the roles of epithelial-connective tissue connection by evaluating collagen fibers using picrosirius red staining among different types of epithelial dysplasia. The correlation of their clinical parameters will also be assessed. The results of this study may reflect the interaction between epithelial dysplastic changes and connective tissue that may lead to the prognosis of the lesion. Moreover, it may be applied for laboratory supporting data for the treatment planning and follow-up period for oral health personnel when treating dysplastic lesion.

## Materials and Methods

Eighty cases of paraffin embedded tissue block from the archives of the Department of Oral and Maxillofacial Pathology, Faculty of Dentistry, Mahidol University between January, 2008 and December, 2015 were retrieved. We included all cases which were fitted to our inclusion criteria (proper size of the specimen and data from biopsy request from were completed in details). The cases of OED and hyperkeratosis were classified into 4 groups equally in number. The histopathologic diagnoses of OED were classified based on the WHO classification of head and neck tumors (2017). Hematoxylin and eosin (H&E) stained slides of all cases were carefully reviewed by two oral pathologists and classified into 4 groups which are (1) hyperkeratosis, (2) mild epithelial dysplasia, (3) moderate epithelial dysplasia and (4) severe epithelial dysplasia. Three cases of focal fibrous hyperplasia were used as positive controls. This study was reviewed and approved by the Institutional Ethical Committee Review Board, Faculty of Dentistry/ Faculty of Pharmacy,

Mahidol University (MU-DT/PY-IRB 2015/014.0104).

In brief, two sections of 4  $\mu\text{m}$ -thick tissues were prepared from paraffin block and stained with H&E and picrosirius red stain (PSR), respectively. The H&E staining section were reviewed a under light microscope for the confirmation of the histopathological diagnosis and study field selection. For PSR staining, the tissue was deparaffinized, hydrated and incubated in Sirius red picrate solution for 30 minutes at the room temperature. The sections were rinsed with distilled water before being stained with Mayer's hematoxylin, dehydrated, and mounted with Permount<sup>®</sup> (Fisher Chemical, Geel, Belgium).

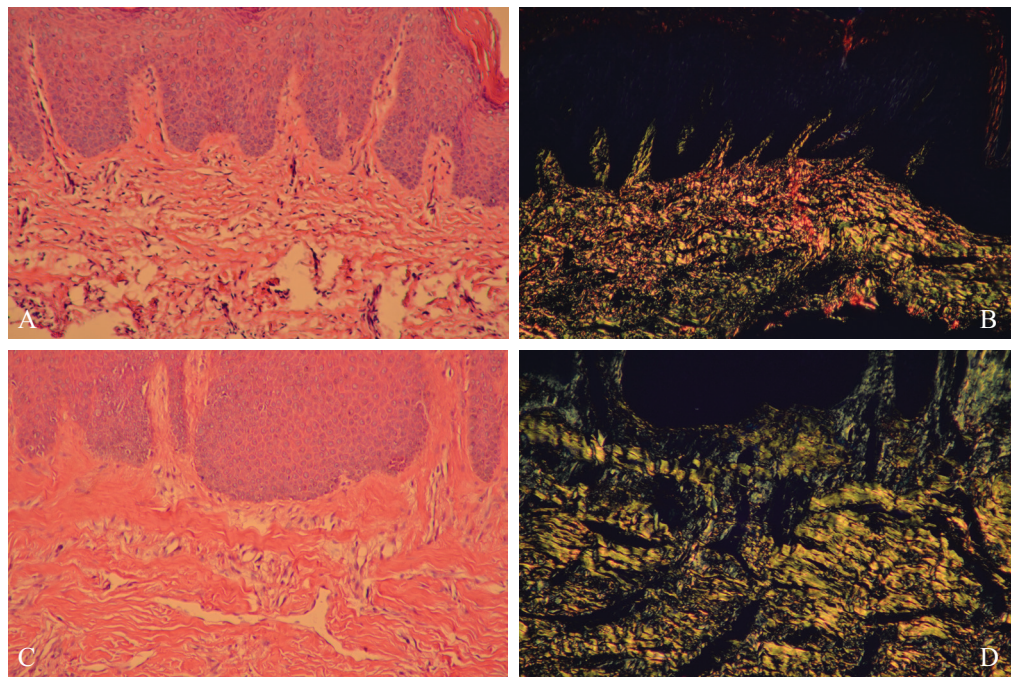
In the focal fibrous hyperplasia, the collagen fibers in lamina propria were examined, while in hyperkeratosis and all types of epithelial dysplasia, the collagen fibers in subepithelial connective tissue were evaluated.

The results were obtained and evaluated based on the birefringence of collagen fibers in subepithelial connective tissue area. Firstly, the two examiners observed the birefringence of the lesion under a polarized light microscope and determined the birefringence of collagen fibers together. The birefringence was classified into 3 groups; the first group, most of the area of collagen fibers showed orange-red birefringence which could be inter-

preted as large diameter and mature collagen patterns. The second group, the area of collagen fibers mostly showed yellow-green birefringence that represented the small diameter and immature collagen patterns. The last group showed mixed orange-red and yellow-green birefringence that represented the mixed large-small diameter and mixed mature-immature collagen patterns. Secondly, each slide was observed at five random areas (at x100 magnification) by two examiners separately. Then, the birefringence score of each slide were calculated and presented by their average number. All data were photographed, recorded and summarized by two examiners (intercalibration Kappa=91). The obtained data were statistically analyzed using Chi-square test with a significant level set to 0.05.

## Results

Collagen fibers were stained with picrosirius red staining and observed under a polarized light microscope. In this study, three cases of focal fibrous hyperplasia were used as control. All three cases showed predominantly orange-red birefringence at the lamina propria. Hyperkeratosis group showed mixed orange-red and green-yellow (Figure 1B) and green-yellow (Figure 1D) birefringence, equally.



**Figure 1:** (A and C) Histopathology of hyperkeratosis (H&E, Original magnification x100), (B) The birefringence of collagen in the connective tissue was mixed yellowish-green to orange-red that represents the mature and immature profiles of collagen, (D) The birefringence of collagen in the connective tissue was green-yellow that represents the immature profiles of collagen. (Picrosirius red staining, polarized light, Original magnification x100).

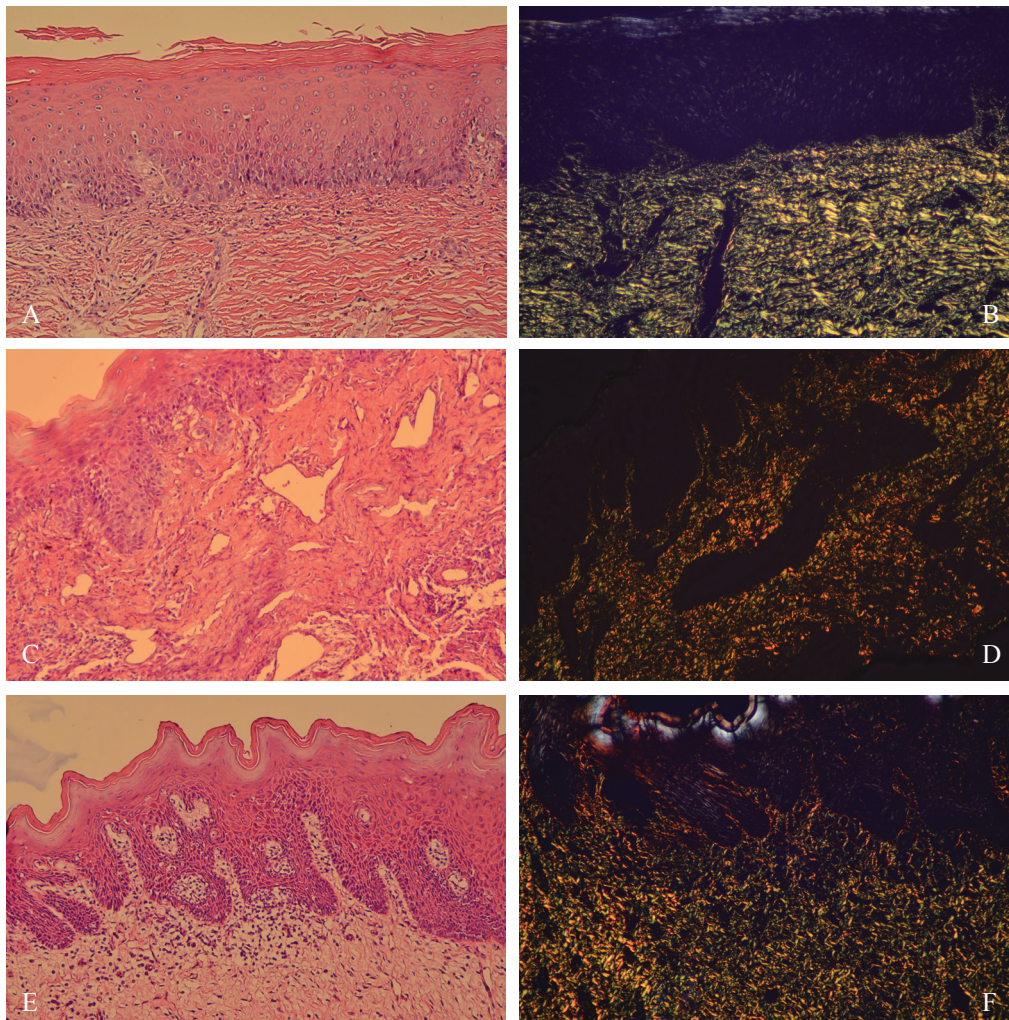
In mild epithelial dysplasia, most cases (50%) in this group revealed green-yellow birefringence (Figure 2B). Most of the cases in moderate epithelial dysplasia and severe epithelial dysplasia, the collagen fibers exhibited mixed orange-red and green-yellow birefringence (Figure 2D and Figure 2F, respectively)

### Age

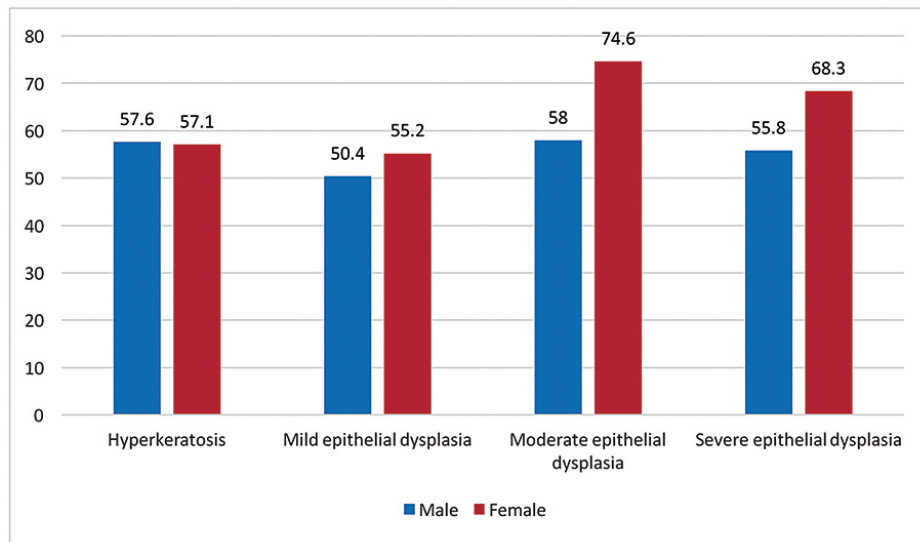
The average age of the female group was higher than the male group in all 3 types of epithelial dysplasia. In the group of hyperkeratosis, the male average age was slightly higher than female. While, the other group, the average age of male was lower than female as depicted in Figure 3.

### Sex

From demographic finding showed that there were more female cases than male in all 3 types of epithelial dysplasia; mild epithelial dysplasia (13 females from 20 total cases, 65.0%), moderate epithelial dysplasia (11 females from 21 total cases, 52.4%), and severe epithelial dysplasia (11 females from 16 total cases, 68.8%). In hyperkeratosis group and all 3 types of epithelial dysplasia, female patients showed predominantly mixed orange-red and green-yellow birefringence. While, male group showed predominantly green-yellow birefringence in hyperkeratosis (8 cases from 10 total cases, 80.0%) and mild epithelial dysplasia groups (6 cases from 10 total cases, 60.0%).



**Figure 2:** (A, C, and E, respectively) Histopathology of mild, moderate and severe epithelial dysplasia. (H&E, Original magnification x100), (B) The birefringence of collagen in the connective tissue of mild epithelial dysplasia was green- yellow that represents the immature profiles of collagen. (Picosirius red staining, polarized light, Original magnification x100), (D and F, respectively) The birefringence of collagen of moderate and severe epithelial dysplasia were mixed yellowish green to orange-red that represents the mature and immature profiles of collagen. (Picosirius red staining, polarized light, Original magnification x100).



**Figure 3:** Distribution of 80 cases according to average age.

Most cases of moderate epithelial dysplasia (12 cases from 21 total cases, 57.1%) and severe epithelial dysplasia (11 cases from 16 total cases, 68.8%), the collagen fibers revealed mixed orange-red and green-yellow birefringence. Most cases of mild epithelial dysplasia (10 cases from 20 total cases, 50.0%), the collagen fibers showed green-yellow birefringence. Histopathologic features according to sex and the birefringence profiles are shown in Table 1.

### Anatomical sites

When compared the clinical data by their anatomical sites. The tongue was the most common site (26 cases from 80 total cases, 32.5%) in this study, followed by the buccal and labial mucosa (21 cases from 80 total cases, 26.3%) and the hard and soft palate (13 cases from 80 total cases, 16.3%) respectively when focused on the histopathological diagnosis. In hyperkeratosis, edentulous area was the most common site (10 cases from 23 total cases, 43.5%). Tongue was the most common site of both moderate epithelial dysplasia (8 cases from 21 total cases, 38.1%) and severe epithelial dysplasia (11 cases from 16 total cases, 68.8%). If considered by their birefringence, from the tongue site, moderate and severe epithelial dysplasia groups showed predominantly mixed orange-red and green-yellow birefringence. While in the mild epithelial dysplasia at the buccal mucosa showed predominantly green-yellow birefringence. Histopathologic features correlate with anatomical sites and birefringence

profile are shown in Table 1.

### Clinical features

The homogeneous leukoplakia is the most common clinical feature found in this study (39 cases from 80 total cases, 48.8%), followed by non-homogeneous leukoplakia (21 cases from 80 total cases, 26.3%) and ulcer (11 cases from 80 cases, 13.8%). In the homogeneous leukoplakia that was mild epithelial dysplasia histopathology showed predominantly green-yellow birefringence. While, severe epithelial dysplasia that was in the non-homogeneous leukoplakia group showed predominantly mixed orange-red and green-yellow birefringence. Histopathologic features, clinical features and birefringence profile are shown in Table 1.

### Signs and symptoms

The pre-diagnosed group is the group that showed the most signs and symptoms in this present study (33 cases from 80 total cases, 37.5%). This pre-diagnosed group included patients who have had histories of being previously biopsied, or having lesion(s) which did not response to any conservative treatment. Most of the birefringence profile of mild epithelial dysplasia in the pre-diagnosed group were green-yellow. While, of the moderate and severe epithelial dysplasia were mixed between orange-red and green-yellow. Histopathological features, signs and symptoms and birefringence profile are shown in Table 1.

## Habits

Since we obtained the biopsy specimens from outside and, sometimes, patients' habit was not included in the biopsy request form, we mostly lacked in the habit data in this study (48 cases from 80 total cases, 60.0%). Informed habits were smoking (14 cases from 80 total cases, 17.5%) and trauma (6 cases from 80 total cases, 7.5%). Histopathologic features, habits and birefringence profile are shown in Table 1.

The birefringence of collagen fibers among different type of OED. We found that hyperkeratosis and all 3 types of epithelial dysplasia revealed orange-red birefringence profile, the collagen fibers showed higher in orange proportion. For the cases that showed mixed profiles, orange-red and green-yellow birefringence profiles were seen equally as well as those cases of hyperkeratosis and all 3 types of epithelial dysplasia that showed predominantly in green or yellow birefringence. The evaluation of collagen fibers and the proportion of birefringence profile of collagen fibers are shown in Table 2.

Birefringence profile in each group were statistically analyzed as followed; mild and severe epithelial dysplasia showed a significant difference of birefringence profile ( $p=0.018$  and  $p=0.019$ , respectively). Between hyperkeratosis and moderate epithelial dysplasia, there were no difference ( $p>0.05$ ). In mild epithelial dysplasia group, comparing between orange-red and green-yellow birefringence, showed significantly difference in birefringence ( $p=0.004$ ). Moreover, in severe epithelial dysplasia group when compared between orange-red and mixed orange-red and green-yellow birefringence showed statistically significance ( $p=0.013$ ). From this statistical analysis, the different between their birefringence profiles will be beneficial in further discussion.

## Discussion

To the best of our knowledge, there were only a few studies focused on the PSR and dysplastic lesions and there has not been a study that reported the relationship between demographic data and the birefringence of different type of oral epithelial dysplasia and hyperkeratotic lesion by using PSR staining investigated under polarized light.

The most common site of dysplastic lesions in the present study was tongue (25 cases from 57 total cases, 43.9%), followed by buccal mucosa (17 cases from 57

total cases, 29.8%). The results are consistent with many previous studies that reported that the lateral border of the tongue including the floor of the mouth were the most common sites of the dysplastic lesions.<sup>(13)</sup> The dysplastic changes in these areas may increase the risk of malignant transformation.

For the clinical features, homogeneous leukoplakia is the most common clinical features of OED (26 cases from 57 total cases, 45.6 %), followed by nonhomogeneous leukoplakia (18 cases from 57 total cases, 31.6%). Many previous studies found that nonhomogeneous leukoplakia had a high prevalence and potential of turning to malignant lesions compared to homogeneous leukoplakia.<sup>(2,14)</sup> OED is a spectrum of cytological and architectural alterations. This dysplastic change is associated with the transformation of squamous cell carcinoma. The stromal tissue is one of the most important components for the progression of SCC. Stromal destruction by the tumor cells may enhance the movement of the tumor cells toward the blood vessels or the lymphatic vessels underneath. Collagen, one of the major elements of the stroma, is primarily affected in the stromal change at the site of tumor cell invasion.<sup>(11)</sup>

About 34% of the total ECM proteins are collagen. The ECM acts as a physical scaffold that binds epithelial cells and connective tissues together. Hence, Piérard suggests that the birefringence of the collagen fibers cannot identified types of collagens.<sup>(15)</sup> He suggests that the proper method that used to determine specific collagen types is immunohistochemical technique.<sup>(16)</sup> Apart from this suggestion, PSR staining investigated under polarized light can also be used. However, PSR technique is not technically sensitive and the result is stable when compared to Immunohistochemistry. We can simply interpret the collagen maturation and interaction between the epithelial-connective tissue interaction from PSR technique. On the other hand, to determine the type of collagen caused from the other factors such as signaling molecules and transcription factors that are responsible for different collagen profiles in normal and diseases, Immunohistochemistry is recommended.

When normal collagen fibers stained with picosirius red are viewed under polarized light microscope, the collagen fibers show thin fibers and green to greenish-yellow birefringence. During maturation of collagen fibers, the change in proteoglycan content causes dehydration of

**Table 1:** Profiles of the 80 cases which are classified by sex, sites, clinical features, signs and symptoms and birefringence profile.

Histopathologic features	Hyperkeratosis			Mild epithelial dysplasia			Moderate epithelial dysplasia			Severe epithelial dysplasia			Total
	OR	Mixed OR-GY	GY	OR	Mixed OR-GY	GY	OR	Mixed OR-GY	GY	OR	Mixed OR-GY	GY	
<b>Sex</b>													
Male	1	6	8	-	1	6	1	5	4	1	4	-	37
Female	2	4	2	1	8	4	2	7	2	1	7	3	43
Total	3	10	10	1	9	10	3	12	6	2	11	3	80
<b>Site</b>													
Tongue	-	-	1	-	3	3	1	4	3	1	8	2	26
Buccal and labial mucosa	-	3	1	-	3	4	2	3	1	-	3	1	21
Hard and soft palate	-	1	1	1	3	2	-	3	2	-	-	-	13
Edentulous area	2	4	4	-	-	1	-	1	-	-	-	-	12
Gingiva	1	1	1	-	-	-	-	1	-	-	-	-	4
Retromolar area	-	-	2	-	-	-	-	-	-	-	-	-	2
Vestibule	-	1	-	-	-	-	-	-	-	-	-	-	1
Floor of mouth	-	-	-	-	-	-	-	-	-	1	-	-	1
Total	3	10	10	1	9	10	3	12	6	2	11	3	80
<b>Clinical features</b>													
Homogeneous leukoplakia	3	7	7	1	4	7	1	4	1	1	3	-	39
Non-homogeneous leukoplakia	-	-	3	-	1	-	1	4	4	-	6	2	21
Ulcer	-	-	-	-	3	1	-	3	1	-	2	1	11
Erythroplakia	-	1	-	-	-	-	-	1	-	1	-	-	3
Mass	-	1	-	-	-	1	1	-	-	-	-	-	3
Hyperpigmentation	-	1	-	-	1	-	-	-	-	-	-	-	2
Normal mucosa	-	-	-	-	-	1	-	-	-	-	-	-	1
Total	3	10	10	1	9	10	3	12	6	2	11	3	80
<b>Signs and symptoms</b>													
Previously disease	-	1	2	-	5	6	2	5	2	1	8	1	33
N/A	1	6	7	-	2	3	-	-	-	-	-	-	19
No any symptoms	1	2	1	1	1	1	1	4	2	-	-	-	14
Burning sensation	-	-	-	-	1	-	-	3	2	1	3	1	11
Pain	1	1	-	-	-	-	-	-	-	-	-	1	3
Total	3	10	10	1	9	10	3	12	6	2	11	3	80
N/A = Not available data													
<b>Habits</b>													
N/A	1	5	3	1	6	6	2	7	4	2	9	2	48
Smoking	-	1	3	-	3	1	-	4	1	-	1	-	14
Trauma	1	-	2	-	-	1	1	-	-	-	1	-	6
Smoking & hard chewing	-	3	1	-	-	1	-	-	-	-	-	-	5
Betel nut chewing	-	-	-	-	-	-	-	1	1	-	-	1	3
Smoking & alcohol	1	-	-	-	-	1	-	-	-	-	-	-	2
Alcohol	-	1	-	-	-	-	-	-	-	-	-	-	1
Smoking & betel nut chewing	-	-	1	-	-	-	-	-	-	-	-	-	1
Total	3	10	10	1	9	10	3	12	6	2	11	3	80

N/A = Not Applicable, OR = Orange-Red, Mixed OR-GY = Mixed Orange-Red and Green-Yellow, GY= Green-Yellow

**Table 2:** Proportion of birefringence in hyperkeratosis and different types of oral epithelial dysplasia.

Histopathologic features	Orange	Red	Mixed		Green	Yellow
			Orange-red	Green-yellow		
Hyperkeratosis	61.7	38.3	45.0	55.0	52.5	47.5
Mild epithelial dysplasia	70.0	30.0	45.6	54.4	54.0	46.0
Moderate epithelial dysplasia	76.7	23.3	45.0	55.0	46.7	53.3
Severe epithelial dysplasia	77.5	22.5	43.6	56.4	53.3	46.7

\*Data shown in percentage from total cases

fibers resulting a change in diameter of collagen fibers and intensity of the birefringence. The collagen fibers will show thick fibers range from yellowish orange to orange red polarization colors.<sup>(17-18)</sup> In pathological condition, the degradation of collagen fibers causes disorganization and loss of polarization sensitivity. Birefringence in pathologic condition shows a different pattern from normal collagen fibers.<sup>(19)</sup>

Most of the previous studies focused on the birefringence of collagen fibers in oral squamous cell carcinoma or oral potentially malignant disorders.<sup>(7-12)</sup> There has only been one study that performed this in OED.<sup>(12)</sup> Thus, this is one of the gap knowledges we found and performed our present study.

The birefringence of collagen fibers in this study is different from some previous studies.<sup>(11,12,20)</sup> In this study, the collagen fibers in mild epithelial dysplasia group revealed yellow-green birefringence and in severe epithelial dysplasia group revealed mixed orange-red and green-yellow birefringence, respectively. The study of Varghese SS *et al.*, presented that mild epithelial dysplasia group revealed yellow-green birefringence and in severe epithelial dysplasia group revealed green birefringence.<sup>(12)</sup> Yokoyama M presented that hyperkeratosis lesion showed red birefringence and decreased with more dysplastic grading.<sup>(20)</sup> The birefringence of collagen fibers from our study was different from previous studies. This may cause by the difference between the specimen sites. In our present study, most of the samples were from tongue and buccal mucosa, which their collagen fiber was naturally loose when compared with Yokoyama M<sup>(20)</sup> that obtained from gingiva. The different sites presented the different type of collagen environment. From our statistical analysis which compared the birefringence between different type of OED, showed significant differences in their birefringence profiles.

Although PSR staining reveals the alignment of collagen fibers, paraffin section could not determine the arrangement of collagen fibers which allied in the same direction. Thus, in this study, there were limitation about the issue of collagen organization and direction, mostly when the collagen fibers arranged in the same direction. This was not conclusive that our present data revealed the trend of the relationship between PSR and maturity of collagen fiber profiles among studied groups.

The decreasing of thick fibers in conjunction with the increasing of thin fibers in dedifferentiated squamous cell carcinoma could be due to the response of connective tissue stroma in early stage. In later stage, production of abnormal collagen and defective maturation of collagen may facilitate the tumor growth.<sup>(21)</sup> From presented result revealed the same trend with previous studies. When considered the anatomical site of the lesions and prevalence of OED, this relationship is related to the prognosis of the disease. From our study, the birefringence of collagen fibers revealed mixed orange-red and green-yellow birefringence in OED groups, which means the collagen fibers were not mature. Although, when considered the PSR staining birefringence, the orange-red represented the maturity trend of collagen. On the other hand, their birefringence profile also showed mixed patterns of green-yellow. This means the immature and small diameter collagen were recognized.

This present study reveals the distinct relationship between the different of the alignment and maturation of collagen fibers with histopathological diagnosis. The higher grade of OED from mild to severe dysplasia will affect the interaction between epithelial-connective tissue. In this study, incomplete maturation of collagen fibers can be detected and implied to its prognosis and may distant metastasis of the lesions. Although PSR staining has some limitation, it is a simple technique and can present some



trends in supportive laboratory information. This is beneficial for applying to further treatment plan and follow up.

## Conclusions

This present study reveals the connection between dysplastic epithelium and connective tissue by the sense of the maturation of collagen fibers among various types of histopathological diagnosis. We assumed that the higher grade of OED may affect to the collagen fiber maturation. Increase grade of OED represented in green-yellow birefringence refers to immature collagen. Apart from the laboratory supporting data, clinicians should combine their clinical experience, clinical features for an appropriate treatment for patients.

## Acknowledgments

This study was supported by grants from Faculty of Dentistry, Mahidol University.

## Conflicts of interest

The authors declare no conflicts of interest.

## References

- Thomson PJ, McCaul JA, Ridout F, Hutchison IL. To treat... or not to treat? Clinicians' views on the management of oral potentially malignant disorders. *Br J Oral Maxillofac Surg.* 2015;53:1027-31.
- Reibl J, Gale N, Hille J, Hunt JL, Lingen M, Muller S, *et al.* Oral potentially malignant disorders and oral epithelial dysplasia. In: El-Naggar AK, Chan JKC, Grandis JR, Takata T, Slootweg P, editors. WHO classification of head and neck tumors. 4<sup>th</sup> ed. Lyon: IARC; 2017. p.112-5.
- Kardam P, Mehendiratta M, Rehani S, Kumra M, Sahay K, Jain K. Stromal fibers in oral squamous cell carcinoma: A possible new prognostic indicator? *J Oral Maxillofac Pathol.* 2016;20:405-12.
- Junqueira LC, Cossermelli W, Brentani R. Differential staining of collagens type I, II and III by Sirius Red and polarization microscopy. *Arch Histol Jpn.* 1978;41:267-74.
- Dayan D, Hiss Y, Hirshberg A, Bubis JJ, Wolman M. Are the polarization colors of picosirius red-stained collagen determined only by the diameter of the fibers? *Histochemistry.* 1989;93:27-9.
- Viswanathan S, Venkatapathy P. Role of collagen fibers in the expansion of odontogenic cyst – a histochemical study. *Internet J Pathol.* 2011;11.
- Kullage S, Jose M, Shanbhag VKL, Abdulla R. Qualitative analysis of connective tissue stroma in different grades of oral squamous cell carcinoma: a histochemical study. *Indian J Dent Res.* 2017;28:355-61.
- Khalid A, Siddiqui S, Bordoloi B, Faizi N, Samadi F, Saeed N. An Immunohistochemical and polarizing microscopic study of the tumor microenvironment in varying grades of oral squamous cell carcinoma. *J Pathol Transl Med* 2018;52:314-22.
- Bordoloi B, Siddiqui S, Jaiswal R, Tandon A, Jain A, Chaturvedi R. A quantitative and qualitative comparative analysis of collagen fibers to determine the role of connective tissue stroma in oral squamous cell carcinoma using special stains and polarized microscopy. *J Oral Maxillofac Pathol.* 2020;24:398.
- Smitha BR, Donoghue M. Clinical and histopathological evaluation of collagen fiber orientation in patients with oral submucous fibrosis. *J Oral Maxillofac Pathol.* 2011;15:154-60.
- Sharma R, Rehani S, Mehendiratta M, Kardam P, Kumra M, Mathias Y, *et al.* Architectural analysis of picosirius red stained collagen in oral epithelial dysplasia and oral squamous cell carcinoma using polarization microscopy. *J Clin Diagn Res.* 2015;9:EC13-6.
- Varghese SS, Sarojini SB, George GB, Vinod S, Mathew P, Babu A, Sebastian J. Evaluation and comparison of the biopathology of collagen and inflammation in the extracellular matrix of oral epithelial dysplasias and inflammatory fibrous hyperplasia using picosirius red stain and polarising microscopy: a preliminary study. *J Cancer Prev.* 2015;20:275-80.
- Dost F, Lê Cao KA, Ford PJ, Farah CS. A retrospective analysis of clinical features of oral malignant and potentially malignant disorders with and without oral epithelial dysplasia. *Oral Surg Oral Med Oral Pathol Oral Radiol.* 2013;116:725-33.
- Warnakulasuriya S, Ariyawardana A. Malignant transformation of oral leukoplakia: a systematic review of observational studies. *J Oral Pathol Med.* 2016;45:155-66.
- Piérard GE. Sirius red polarization method is useful to visualize the organization of connective tissues but not the molecular composition of their fibrous polymers. *Matrix.* 1989;9:68-71.
- Coleman R. Picosirius red staining revisited. *Acta Histochem.* 2011;113:231-3.
- Hirshberg A, Sherman S, Buchner A, Dayan D. Collagen fibres in the wall of odontogenic keratocysts: a study with picosirius red and polarizing microscopy. *J Oral Pathol Med.* 1999;28:410-2.
- Allon I, Vered M, Buchner A, Dayan D. Stromal differences in salivary gland tumors of a common histopathogenesis but with different biological behavior: a study with picosirius red and polarizing microscopy. *Acta Histochem.* 2006;108:259-64.
- Junqueira LC, Cossermelli W, Brentani R. Differential staining of collagens type I, II and III by Sirius Red and polarization microscopy. *Arch Histol Jpn.* 1978;41:267-74.

20. Yokoyama M. Alterations in stromal reaction during tumor progression in oral mucosa. *J Hard Tissue Biol.* 2011;20:23-30.
21. Jussila T, Kauppila S, Bode M, Tapanainen J, Risteli J, Risteli L, *et al.* Synthesis and maturation of type I and type III collagens in endometrial adenocarcinoma. *Eur J Obstet Gynecol Reprod Biol.* 2004;115:66-74.