



Editor:

Wannakamon Panyarak,
Chiang Mai University, Thailand.

Received: February 14, 2022

Revised: April 20, 2022

Accepted: May 30, 2022

Corresponding Author:

Assistant Professor
Dr. Piyanuj Permpaich,
Department of Restorative Dentistry
and Periodontology, Faculty of
Dentistry, Chiang Mai University,
Chiang Mai 50200, Thailand.
E-mail: piyanuj.permpa@cmu.ac.th

A Study of Furcation-defect Volume Obtained from CBCT Images

Tanachai Pastarapijit¹, Piyanuj Permpaich²

¹Graduate Student, Department of Restorative Dentistry and Periodontology,
Faculty of Dentistry, Chiang Mai University, Thailand

²Department of Restorative Dentistry and Periodontology, Faculty of Dentistry, Chiang Mai
University, Thailand

Abstract

Objectives: To evaluate the accuracy of estimating furcation-defect volume obtained from cone beam computed tomography (CBCT) images in a clinical setting.

Methods: Six periodontitis patients with buccal degree II furcation involvement of maxillary molars that required additional surgical therapy were recruited, and CBCT was performed. CBCT images of the defects were analyzed, and their volumes were estimated using the Cavalieri principle (CBCT-based volume). Open flap surgery was performed at the furcation area and, following debridement, the silicone impression material (Silagum[®] [light body]) was used to take an impression of each defect. The volume of each impression (impression volume) was calculated using the relationship between the mass, volume, and density of the material. For each defect, the CBCT-based volume was compared to the impression volume using a paired *t*-test with $p < 0.05$. Two raters analyzed and estimated the CBCT-based volume. The intra- and inter-rater reliability were determined by the intraclass correlation coefficient statistics (ICC).

Results: The intra- and inter-rater reliability of the assessing method showed excellent results (ICC=0.99 and 0.965, respectively). There was no statistically significant difference between the CBCT-based-volume and the impression-volume groups ($p=0.831$).

Conclusions: Based on the findings of our study, the volume of the furcation defect can be accurately estimated clinically by means of CBCT images using the Cavalieri principle.

Keywords: accuracy, cavalieri principle, cone beam computed tomography (CBCT), furcation-defect volume, volume measurement

Introduction

The most common cause of tooth loss is periodontitis. Especially in molars, as the disease progresses to the furcation areas, resulting in furcation bone loss. Due to the complexity of furcation anatomy, it is very difficult to treat and maintain this area. Proper treatment, along with effective supportive periodontal therapy, allows furcation-involved molars to be preserved for a longer period with a better long-term prognosis.⁽¹⁻⁸⁾

There are a variety of approaches to treating molars with furcation involvement, depending on the treatment decision of the dentist. A variety of parameters must be considered, including the severity of the furcation involvement, furcation-defect morphology, tooth-related factors, and patient-related factors, such as smoking habits.⁽⁹⁾ The regenerative method, however, is considered the optimal goal of periodontal therapy.

Several studies have demonstrated that moderately severe furcation involvement (classified as degree II furcation involvement by Hamp *et al.*⁽¹⁰⁾) can be effectively treated with regenerative periodontal treatment, resulting in an improved tooth prognosis.⁽¹¹⁾ The morphology of the defect is one of the most important factors in determining how to treat molars with furcation involvement. Determining the morphology of these furcation areas using clinical examination and conventional radiographs is more accurate in mandibular molars with two roots than in maxillary molars with three roots. The detection of furcation involvement in the maxillary molars using clinical examination and conventional radiography is challenging due to the complexity of the furcation morphology, especially in moderate to severe furcation-involved maxillary molars.^(12,13) This results in misdiagnosis and inappropriate treatment planning.

CBCT (cone beam computed tomography) is increasingly used in dentistry as dental 3D-imaging technology has evolved. CBCT accurately displays 3D details of lesions in the jawbone that are comparable to the actual lesions under surgical exploration.⁽¹⁴⁻¹⁶⁾ The new generation of CBCT machines has been developed so that the radiation exposure is significantly lower than previous CBCT machines.^(17,18) CBCT effectively reveals the morphology of the maxillary molar furcation area, allowing for the evaluation of severity and providing the precise measurement of the lesion in three dimensions comparable to that achieved by direct access using surgi-

cal exposure.⁽¹⁹⁻²¹⁾ Accurate assessment of the furcation anatomy leads to the correct diagnosis and proper treatment plan to correct furcation-involved lesions. In addition to enabling the correct diagnosis that leads to an appropriate treatment plan, CBCT is also very beneficial in assessing the success of treatment and providing continuous evaluation of treatment's effectiveness.⁽²²⁾ In particular, in regenerative periodontal treatment, identifying the changes of the defects after treatment in three dimensions is more accurate and more informative than conventional measurement. CBCT allows the generation of a reconstructive image of the interested area without having to perform reentry surgery that helps to reduce the risk of surgical complications, such as bleeding and infections. CBCT does not interfere with the healing process in the same way that surgical exploration does.

The volumetric value based on the change in volume after treatment is suitable for use in assessing the 3D changes of the lesion. A study by Gantes *et al.* in 1988 was the first to describe and employ furcation volume to evaluate the effectiveness of regenerative periodontal therapy on mandibular molars with degree II furcation involvement.⁽²³⁾ However, due to the procedure's complexity and high risk of error, it was not widely used as an indicator for evaluating regeneration therapy. Using a specific algorithm, it was discovered that the dataset obtained from CBCT could be used to compute the volume of anatomical structures or lesions.^(22,24) As a result, new regeneration studies are beginning to employ furcation volume as an additional measure of success and/or as a comparative value of the efficacy of different regenerative procedures.⁽²⁵⁻²⁷⁾ However, with the Cavalieri principle of the stereological method, the volume of an arbitrarily shaped object can be easily estimated by a mathematical method using the sum of the cross-sectional areas from parallel and equal-thickness sections of the desired object.⁽²⁸⁻³¹⁾ This method's accuracy has been demonstrated *in vitro* using simulated lesions in the model^(32,33); however, no clinical trials have been undertaken to evaluate this method on furcation defects that are arbitrary, tiny, and complex.

The purpose of this study was to evaluate the accuracy of the furcation-defect volume of class II furcation-involved maxillary molars acquired from CBCT images using the Cavalieri principle compared to the volume acquired from surgical exploration.

Materials and Methods

Six subjects were recruited from patients at the Department of Restorative Dentistry and Periodontology of our institution. The patients in this study had the following characteristics: 1) They were over the age of 20, and 2) they had been diagnosed with generalized chronic periodontitis with at least one degree II buccal furcation involvement on a maxillary molar that required periodontal surgery. Patients with root caries at the furcation area, with metal crowns or cervical amalgam filling on the tooth under study, or in the midst of a pregnancy or systemic condition for which surgery was not advisable were excluded from the study.

A curved scaled Nabers probe (PQ2N; HU-Friedy) was used to examine the severity of furcation involvement, and the degree II furcation involvement was described as horizontal loss of periodontal supporting tissue surpassing 3 mm, but not “through and through” destruction, according to the classification system of Hamp *et al.*⁽¹⁰⁾ The details of the study were explained to all patients, and they all volunteered to participate and completed an informed consent form. The protocol and consent form were authorized by the Faculty of Dentistry Human Experimentation Committee of our institution (No. 72/2019), and this trial was registered with the Thai Clinical Trials Registry (TCTR20220208004).

The hygienic phase of periodontal treatment was completed, followed by periodontal reevaluation. Prior to surgery, CBCT images of the posterior maxillary molars were obtained using NewTom Giano HR (Quantitative Radiology, Verona, Italy) with the following parameters: a FOV (field of view) of 4×4 cm, a tube voltage of 90 kV, a tube current of 4–6 mA, a scan time of 8 sec, and a voxel size of 0.125 mm.

Estimation of defect volume using the Cavalieri principle

Volumetric data were reconstructed, and each section was measured using a setting of 0.15 mm thickness. The Cavalieri principle was used for calculating the furcation-defect volume. Initially, the planimetry method was used to measure the surface area of each section using the ImageJ program, which was created by Wayne Rasband and the National Institute of Health. For each plane of cutting, an imaginary line was drawn to connect the two dots designated for the outermost radiopaque position

surrounding the radiolucent area of the furcation defect. The sum of the areas was used to estimate the volume using the following formula, which has been described in previous reports.⁽²⁹⁻³¹⁾

$$V = t \times \sum A,$$

Where *t* is the section thickness of consecutive sections, and $\sum A$ is the total sectional area of the consecutive sections.

The CBCT volumetric estimated value of each defect was done in triplicate. The final value was the average value of the three volumes calculated from the three sets of CBCT image series.

To determine the intra-rater reliability, examiner I who was a post-graduate student in the residency training program in periodontology with some training in measuring simulated defect volume in models using CBCT analyzed and estimated the CBCT volumes of all samples in 2 occasions with a time interval of 1 week. To determine inter-rater reliability, examiner II who was a board certified periodontist with experience in measuring defect volume in this study analyzed and estimated the CBCT volume of all samples.

Evaluation of defect volume under surgical exploration

Open flap surgeries were performed on all targeted furcation-involved maxillary molars to gain access for cleaning. During periodontal surgery, the operator cleaned the furcation areas and made impressions of the buccal furcation defects by injecting a low-viscosity silicone-impression material into the furcation areas. After the material had set, the impression was cut along the reference line with surgical blade No.15c and set as the outer border by placing the blade across the prominence of both roots, beginning at the furcation phoenix and finishing at the crest of bone. The reference line was the imaginary line from the highest contour of the mesio-buccal root to the highest contour of the disto-buccal root. A marking pencil could be used to delineate the defects' apertures if the line of highest contour of the roots was not clarified, resulting in the cutting of an imprint not extending over or under the boundary. During surgery, the operator made three impressions of each furcation defect to create the molds that were used to measure defect volume. The impression mold was created using low-vis-

cosity silicone impression material (Silagum®) with a density of 1.37406 g/cm³. The impression molds were weighed using an analytical balance, and the volume of each furcation lesion was then calculated using average data from the three molds. Weighing the model with an analytical balance yielded the model's average mass. The relationship between density, mass, and volume was then used to calculate the volume of the model.

Statistical analysis

A power analysis (based on the study of Kayipmaz *et al.*⁽³²⁾) indicated that 6 defects were the minimum sample size required to detect a difference of less than 5% between the impression-volume and CBCT-based-volume groups. The data set was well-modeled by a normal distribution after performing the Shapiro-Wilk test to examine the differences between groups. As a result, a paired sample *t*-test was utilized to test whether there was a statistically significant difference between the volume obtained from CBCT and the volume received from the impressions during the surgical procedure. To measure the volume using CBCT, the Intraclass correlation coefficient (ICC) was utilized to establish intra- and inter-examiner reliability. The level of significance was set at 5% ($p < 0.05$). All of the analyses were performed with SPSS statistics (IBM Corp. IBM SPSS for Windows, Version 22.0. Armonk, NY, USA)

Results

In this study, overall furcation-defect morphology was investigated. All the defect samples in this study were degree II furcation involvement defects according to Hamp's classification criteria.⁽¹⁰⁾ Hamp's class II furcation involvement is defined as the horizontal loss of periodontal supporting tissue surpassing 3 mm but not "through and through" destruction as measured perpendicular to the long axis of the tooth, and into the deepest point of the furcation defect. In the axial plane of the CBCT radiographic examination, there was no bone covering the wall of the defects for either the mesio-buccal root surface or the disto-buccal root surface within the lesions. However, all samples had bone covering the palatal root surface within the lesions except for sample no. 4, which had no remaining bone. The example CBCT cross-sectional images in the axial plane of samples no. 1's and no. 4's defects are presented in Figure 1.

The calculation of the six furcation-defect volumes from the CBCT image series, all of which were buccal degree II furcation involvement of maxillary molars, is shown in Table 1, and an example of finding the cross-sectional area of sample no. 1's defect using ImageJ program is shown in Figure 2.

Table 2 shows the mean impression weights and the results of computing the furcation-defect volumes of the six defect samples, and Figure 3 illustrates an example impression model of the defect from sample no. 1 in this study.

Examiner I's and examiner II's measurement of CBCT volume are presented in Table 3. The intra-rater reliability of each examiner was found to be excellent (Table 4), as was the agreement between the examiners (Table 5).⁽³⁴⁾

The differences between the impression volumes and the CBCT-based volumes ranged from 0.00826 to 0.1698 mm³ with a mean of 0.0079 mm³ (standard deviation=0.0863 mm³) as shown in Table 6.

Because the different data between the estimated volume and actual volume group had a normal distribution, a pair sample *t*-test was used to examine the statistical significance of the difference between the CBCT-based volume and the impression volume. The tests demonstrated that the CBCT volumes from the Cavalieri estimates did not significantly differ from the actual impression volumes of the defects received from the surgical assessment ($p = 0.831$) (Table 7).

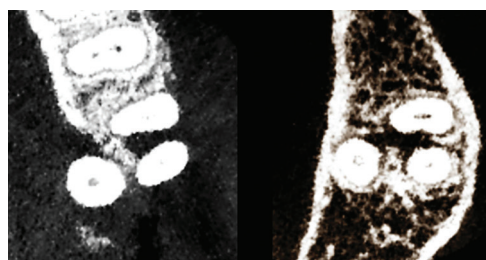


Figure 1: Example CBCT cross-sectional images in the axial plane of (left) sample no. 1's defect showing remaining bone covering the palatal root surface within the lesion and (right) sample no. 4's defect showing no remaining bone.

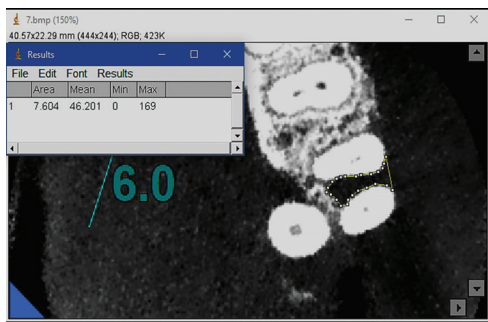


Figure 2: Using ImageJ program to analyze the cross-sectional area of the CBCT image series in the axial plane of sample no. 1’s defect.

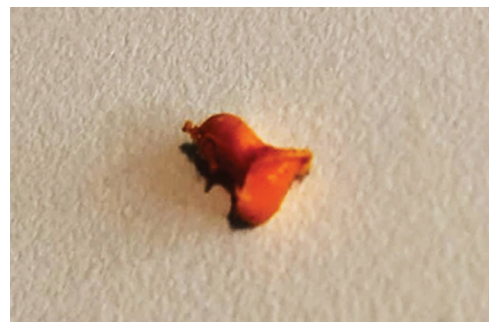

Figure 3: An example impression model of sample no. 1’s defect.

Table 1: Examiner I’s CBCT estimated furcation-defect volumes in triplicate at the same occasion.

Sample No.	CBCT-based volume (mm ³)			
	1	2	3	Mean
1	18.4998	18.3099	18.5985	18.4694
2	3.6641	3.7571	3.7362	3.7191
3	10.9149	10.9133	10.8995	10.9092
4	17.6067	17.2326	17.1257	17.3217
5	9.2543	9.2762	9.2237	9.2514
6	7.6320	7.6277	7.5551	7.6049

Table 2: The mean impression weights and the results of computing the furcation-defect volumes of the six defect samples.

Sample No.	Impression weight (g)				Volume (mm ³)
	1	2	3	Mean	
1	0.0251	0.0255	0.0254	0.0253	18.4377
2	0.0052	0.0052	0.0050	0.0051	3.7361
3	0.0149	0.0149	0.0151	0.0150	10.8928
4	0.0237	0.0245	0.0239	0.0240	17.4915
5	0.0127	0.0126	0.0128	0.0127	9.2431
6	0.0103	0.0103	0.0104	0.0103	7.5206

Table 3: CBCT-based defect volumes estimated by examiners I and II.

Sample No.	Volume (mm ³) CBCT		
	Examiner I		Examiner II
	1 st	2 nd	
1	18.4694	18.5732	17.5372
2	3.7191	3.7965	2.8676
3	10.9092	10.9023	12.8227
4	17.3217	17.4667	20.5589
5	9.2514	8.9251	6.3184
6	7.6049	7.8599	10.1036

Table 4: The results of intra-rater reliability verification in the estimation of furcation-defect volumes from CBCT images using the ICC statistic.

Intraclass Correlation Coefficient							
	Intraclass Correlation	95% Confidence Interval		F Test with True Value 0			
		Lower Bound	Upper Bound	Value	df1	df2	Sig
Single Measures	0.999	0.996	1.000	2786.949	5	5	0.000
Average Measures	1.000	0.998	1.000	2786.949	5	5	0.000

Table 5: The results of inter-rater reliability verification in the estimation of furcation- defect volumes from CBCT images using the ICC statistic.

Intraclass Correlation Coefficient							
	Intraclass Correlation	95% Confidence Interval		F Test with True Value 0			
		Lower Bound	Upper Bound	Value	df1	df2	Sig
Single Measures	0.933	0.620	0.990	25.277	5	5	0.001
Average Measures	0.965	0.765	0.995	25.277	5	5	0.001

Table 6: The defect volumes of six samples measured by two different methods (mm³).

Sample No.	CBCT-based Volume	Impression Volume	Difference
1	18.4694	18.4377	0.0317
2	3.7191	3.7361	0.0170
3	10.9092	10.8928	0.0165
4	17.3217	17.4915	0.1698
5	9.2514	9.2431	0.0083
6	7.6049	7.5206	0.0843

Table 7: The statistical significance of the difference between CBCT-based volume and the actual impression volume.

Paired Samples Test									
Paired Differences									
		Mean	Std. Deviation	Std. Error Mean	95% Confidence Interval of the Difference		T	df	Sig. (2-tailed)
					Lower	Upper			
Pair 1	Impression – CBCT	0.0079000	0.0862635	0.0352169	-0.0826279	0.0984279	0.224	5	0.831

Discussion

The success of periodontal regenerative treatment depends mostly on selecting the proper treatment for morphology of the specific defect. However, in some challenging areas, such as the furcation area, where clarification of defects using standard examination is difficult due to the complexity of their anatomies, CBCT has proven to be the best solution for improving and facilitating the procedure.⁽¹⁵⁾ CBCT is a highly accurate tool for evaluating

bone abnormalities in linear measurement.^(14,35) However, there has never been a study examining the accuracy of CBCT as a tool for providing volumetric measurement in the furcation defect. If its efficacy were established, CBCT would be used in treatment planning and to assess changes following regenerative treatment of the furcation.

In this study, we employed cross-sectional CBCT images of the defects from the axial plane to determine the furcation-defect volumes, unlike prior studies by

Kayipmaz *et al.*⁽³²⁾ and Sezgin *et al.*⁽³³⁾ Since those studies used the plaster index to determine the outer extent, the defect boundaries were then cleared in all planes of the CBCT images, allowing defect volumes to be calculated using the cross-sectional surface area of either the coronal plane, sagittal plane, or axial plane. In our study, because the actual furcation defects we examined could not identify the extent of the supra-bony part of the defects in the buccal aspect, an imaginary line connecting the highest contour of the mesio-buccal root and the disto-buccal root of the tooth needed to be used to determine the volume. Because the highest contour of the root varies in position along the root, the furcation-defect volume could not be computed using cross-sectional images from both the coronal and sagittal planes. According to studies conducted by Sahin *et al.* in 2003 and 2008, which suggested that a plane worked by stereological methods has no adverse effect on quantitative measurement,^(30,36) the axial plane used in our study is assured to produce reliable volumetric estimations utilizing stereological methods.

In our study, there was no statistically significant difference between the furcation-defect volumes derived from CBCT images and those from surgery, indicating that this Cavalieri method, which is non-invasive and does not require additional software support for estimating the furcation-defect volume using CBCT images, is effective and practicable. However, the volume estimations of four defect samples in our study using CBCT images were overestimated compared to the actual volumes derived from the impression, while the other two defect samples were underestimated. The findings were comparable to those of a prior study published in 2011 by Kayipmaz *et al.*, which revealed that CBCT-based volume was not significantly different from the actual volume and was likely overestimated.⁽³²⁾ This study showed a result that is in contrast to other studies that found a lower estimation tendency of the CBCT-based volume when compared to the actual volume.^(37,38) They explained that the cause of this condition was a partial volume effect arising from attenuation in imaging the tissue with different intensities within the same voxel, but that by setting the sections as thin as feasible, this influence could be minimized and a more realistic CBCT-based volume would be achieved. However, because the number of defects in our study was the minimal number calculated for the sample size which showed the CBCT-based furcation-defect volumes

estimated by the Cavalieri principle yielded more value than realistic-the tendency of overestimated volume calculation in our study is not yet conclusive and requires additional confirmation with more defect samples.

When considering the effect of slice thickness on the accuracy of calculating furcation-defect volume from CBCT images, our study selected the CBCT machine's minimum slice thickness of 0.15 mm. This was because previous results by Koç and Kaya in 2021 showed that a slice thickness of less than 0.75 mm would yield a CBCT-based volume not significantly different from the actual volume, and that the smallest slice thickness was likely to yield radiographic volume calculation with the most accurate values.⁽³⁹⁾ Despite the fact that the size range of lesions used by Koç and Kaya⁽³⁹⁾ was vast and the mean volume was larger than the volume of our study, the minimum size of defects (37.6 mm³) is relevant and close to the volume of our study, which ranged from 3.73605 mm³ to 18.4377 mm³, and the vertical defect height, the distance used to create cross-sectional radiographs for calculating furcation-defect volumes, was between 1.65 mm and 4.2 mm. The results of our study were not significantly different from the actual volume. Thus, it may be assumed that the CBCT slice thickness of 0.15 mm is also suitable for calculating small actual furcation defects with a vertical defect height of only 1.65 mm. The findings are similar to those of a 2011 study by Kayipmaz *et al.*, which found that a slice thickness of 0.2 mm can be used to determine volume from CBCT images of a 2 mm diameter artificial lesion correctly.⁽³²⁾ Previously, the volume derived from the impression of the actual lesion was used as the standard reference; however, the accuracy of the value is dependent on the details that can be picked up with each impression material. Our study worked on lesions that were much smaller and more realistic than those developed in the models. As a consequence, when compared to the prior study, the findings of our study provided more practical information.

Furthermore, our study was undertaken to assess the intra- and inter-examiner reliability of furcation-defect-volume estimation in order to increase confidence in its practical application. Unlike the study by Kayipmaz *et al.*, which did not calculate method reliability,⁽³²⁾ our findings demonstrate that the method we used was highly reliable. Emirzeoglu *et al.* conducted a study in 2005 to assess volume measurement of the liver using the

Cavalieri principle, and their findings were similar to our results, concluding that there was no difference between observers for measurements acquired from CBCT volume rendering.⁽⁴⁰⁾

In our study, we considered reducing the amount of radiation given to patients by carefully adjusting exposure factors and limiting the exposed region to the smallest but sufficient dimension in accordance with the ALARA principle. Based on the radiation protocol employed in this study, the effective radiation dosage received by the patient is estimated to be around 50 microsieverts, which is only about 2 times higher than the mean effective dose of panoramic examinations (22.9 microsieverts).⁽⁴¹⁾ Despite the fact that CBCT has a higher radiation dose than conventional radiography, the advantages of a precise defect-volume assessment and additional information, which is unavailable in both intra-and extra-oral conventional radiography, outweigh the risks of a higher radiation dose.

Conclusions

Based on the findings of our study, the volume of the furcation defect can be accurately estimated clinically by means of CBCT images using the Cavalieri principle. However, more studies using larger samples with a variety of defects should be performed to confirm validity in clinical application.

Acknowledgments

This work was supported by a research grant from the Royal College of Dental Surgeons of Thailand and our institution. We would like to extend our gratitude and appreciation to the Dental X-Ray Center and Research Center of our institution for providing research equipment; Miss Ratikorn Kittada for assisting with the collection of CBCT images and Dr. Thanapat Sastraruji for advice on statistical analysis in this study.

Conflicts of interest

The authors declare no conflicts of interest.

References

1. Wang HL, Burgett FG, Shyr Y, Ramfjord S. The influence of molar furcation involvement and mobility on future clinical periodontal attachment loss. *J Periodontol*. 1994;65(1):25-9.
2. Fleischer HC, Mellonig JT, Brayer WK, Gray JL, Barnett JD. Scaling and root planing efficacy in multirrooted teeth. *J Periodontol*. 1989;60(7):402-9.
3. Papapanou PN, Wennstrom JL, Grondahl K. Periodontal status in relation to age and tooth type. a cross-sectional radiographic study. *J Clin Periodontol*. 1988;15(7):469-78.
4. Nordland P, Garrett S, Kiger R, Vanootehem R, Hutchens LH, Egelberg J. The effect of plaque control and root debridement in molar teeth. *J Clin Periodontol*. 1987;14(4):231-6.
5. Hugoson A, Koch G, Bergendal T, Hallonsten AL, Laurell L, Lundgren D, *et al*. Oral health of individuals aged 3-80 years in Jonkoping, Sweden, in 1973 and 1983. II. a review of clinical and radiographic findings. *Swed Dent J*. 1986;10(5):175-94.
6. Lang NP, Cumming BR, Loe H. Toothbrushing frequency as it relates to plaque development and gingival health. *J Periodontol*. 1973;44(7):396-405.
7. Hirschfeld L, Wasserman B. A long-term survey of tooth loss in 600 treated periodontal patients. *J Periodontol*. 1978;49(5):225-37.
8. Baelum V, Fejerskov O. Tooth loss as related to dental caries and periodontal breakdown in adult Tanzanians. *Community Dent Oral Epidemiol*. 1986;14(6):353-7.
9. Al-Shammari KF, Kazor CE, Wang HL. Molar root anatomy and management of furcation defects. *J Clin Periodontol*. 2001;28(8):730-40.
10. Hamp SE, Nyman S, Lindhe J. Periodontal treatment of multirrooted teeth. Results after 5 years. *J Clin Periodontol*. 1975;2(3):126-35.
11. Avila-Ortiz G, De Buitrago JG, Reddy MS. Periodontal regeneration-furcation defects: a systematic review from the AAP Regeneration Workshop. *J Periodontol*. 2015;86(2 Suppl):S108-30.
12. Zappa U, Grosso L, Simona C, Graf H, Case D. Clinical furcation diagnoses and interradicular bone defects. *J Periodontol*. 1993;64(3):219-27.
13. Eickholz P. Reproducibility and validity of furcation measurements as related to class of furcation invasion. *J Periodontol*. 1995;66(11):984-9.
14. Misch KA, Yi ES, Sarment DP. Accuracy of cone beam computed tomography for periodontal defect measurements. *J Periodontol*. 2006;77(7):1261-6.
15. Vandenberghe B, Jacobs R, Yang J. Diagnostic validity (or acuity) of 2D CCD versus 3D CBCT-images for assessing periodontal breakdown. *Oral Surg Oral Med Oral Pathol Oral Radiol Endod*. 2007;104(3):395-401.
16. Mol A, Balasundaram A. *In vitro* cone beam computed tomography imaging of periodontal bone. *Dentomaxillofac Radiol*. 2008;37(6):319-24.
17. Mozzo P, Procacci C, Tacconi A, Martini PT, Andreis IA. A new volumetric CT machine for dental imaging based on the cone-beam technique: preliminary results. *Eur Radiol*. 1998;8(9):1558-64.

18. Schulze D, Heiland M, Thurmann H, Adam G. Radiation exposure during midfacial imaging using 4- and 16-slice computed tomography, cone beam computed tomography systems and conventional radiography. *Dentomaxillofac Radiol.* 2004;33(2):83-6.
19. Walter C, Kaner D, Berndt DC, Weiger R, Zitzmann NU. Three-dimensional imaging as a pre-operative tool in decision making for furcation surgery. *J Clin Periodontol.* 2009;36(3):250-7.
20. Walter C, Weiger R, Zitzmann NU. Accuracy of three-dimensional imaging in assessing maxillary molar furcation involvement. *J Clin Periodontol.* 2010;37(5):436-41.
21. Qiao J, Wang S, Duan J, Zhang Y, Qiu Y, Sun C, *et al.* The accuracy of cone-beam computed tomography in assessing maxillary molar furcation involvement. *J Clin Periodontol.* 2014;41(3):269-74.
22. Agbaje JO, Jacobs R, Michiels K, Abu-Ta'a M, van Steenberghe D. Bone healing after dental extractions in irradiated patients: a pilot study on a novel technique for volume assessment of healing tooth sockets. *Clin Oral Investig.* 2009;13(3):257-61.
23. Gantes B, Martin M, Garrett S, Egelberg J. Treatment of periodontal furcation defects. (II). Bone regeneration in mandibular class II defects. *J Clin Periodontol.* 1988;15(4):232-9.
24. Ogawa T, Enciso R, Shintaku WH, Clark GT. Evaluation of cross-section airway configuration of obstructive sleep apnea. *Oral Surg Oral Med Oral Pathol Oral Radiol Endod.* 2007;103(1):102-8.
25. Pajniğara NG, Kolte AP, Kolte RA, Pajniğara NG. Volumetric assessment of regenerative efficacy of demineralized freeze-dried bone allograft with or without amnion membrane in grade II furcation defects: a cone beam computed tomography study. *Int J Periodontics Restorative Dent.* 2017;37(2):255-62.
26. Shah KK, Kolte RA. Evaluation of demineralized freeze-dried bone allograft in combination with chorion membrane in the treatment of grade II furcation defects: a randomized controlled trial. *Int J Periodontics Restorative Dent.* 2019;39(5):659-67.
27. Wanikar I, Rathod S, Kolte AP. Clinico-radiographic evaluation of 1% alendronate gel as an adjunct and smart blood derivative platelet rich fibrin in grade II furcation defects. *J Periodontol.* 2019;90(1):52-60.
28. Roberts N, Puddephat MJ, McNulty V. The benefit of stereology for quantitative radiology. *Br J Radiol.* 2000;73(871):679-97.
29. Mazonakis M, Damilakis J, Maris T, Prassopoulos P, Gourtsoyiannis N. Comparison of two volumetric techniques for estimating liver volume using magnetic resonance imaging. *J Magn Reson Imaging.* 2002;15(5):557-63.
30. Sahin B, Emirzeoglu M, Uzun A, Incesu L, Bek Y, Bilgic S, *et al.* Unbiased estimation of the liver volume by the Cavalieri principle using magnetic resonance images. *Eur J Radiol.* 2003;47(2):164-70.
31. Acer N, Sahin B, Bař O, Ertekin T, Usanmaz M. Comparison of three methods for the estimation of total intracranial volume: stereologic, planimetric, and anthropometric approaches. *Ann Plast Surg.* 2007;58(1):48-53.
32. Kayıpmaz S, Sezgin Ö, Sarıcaođlu S, Bař O, řahin B, Kűcűk M. The estimation of the volume of sheep mandibular defects using cone-beam computed tomography images and a stereological method. *Dentomaxillofac Radiol.* 2011;40(3):165-9.
33. Sezgin ÖS, Kayıpmaz S, Sahin B. The effect of slice thickness on the assessment of bone defect volumes by the Cavalieri principle using cone beam computed tomography. *J Digit Imaging.* 2013;26(1):115-8.
34. Koo TK, Li MY. A Guideline of selecting and reporting intraclass correlation coefficients for reliability research. *J Chiropr Med.* 2016;15(2):155-63.
35. Pinsky HM, Dyda S, Pinsky RW, Misch KA, Sarment DP. Accuracy of three-dimensional measurements using cone-beam CT. *Dentomaxillofac Radiol.* 2006;35(6):410-6.
36. Sahin B, Mazonakis M, Akan H, Kaplan S, Bek Y. Dependence of computed tomography volume measurements upon section thickness: an application to human dry skulls. *Clin Anat.* 2008;21(6):479-85.
37. Agbaje JO, Jacobs R, Maes F, Michiels K, Van Steenberghe D. Volumetric analysis of extraction sockets using cone beam computed tomography: a pilot study on *ex vivo* jaw bone. *J Clin Periodontol.* 2007;34(11):985-90.
38. Sahin B, Acer N, Sonmez OF, Emirzeoglu M, Basaloglu H, Uzun A, *et al.* Comparison of four methods for the estimation of intracranial volume: a gold standard study. *Clin Anat.* 2007;20(7):766-73.
39. Koç A, Kaya S. Is it possible to estimate volume of bone defects formed on dry sheep mandibles more practically by secondarily reconstructing section thickness of cone beam computed tomography images?. *Dentomaxillofac Radiol.* 2021;50(3):20200400.
40. Emirzeoglu M, Sahin B, Selcuk MB, Kaplan S. The effects of section thickness on the estimation of liver volume by the Cavalieri principle using computed tomography images. *Eur J Radiol.* 2005;56(3):391-7.
41. Shatskiy I. Effective doses and radiation risks from common dental radiographic, panoramic and CBCT examinations. *Radiat Prot Dosimetry.* 2021;195(3-4):296-305.