

Editor:

Anak Iamaroon,
Chiang Mai University, Thailand.

Received: March 28, 2022

Revised: June 29, 2022

Accepted: September 13, 2022

Corresponding Author:

Clinical Professor Wichitsak Cholitgul,
Department of Radiology, Faculty of
Dentistry, Chulalongkorn University,
Bangkok 10330, Thailand.
E-mail: cwichits@chula.ac.th

Metastatic Hepatocellular Carcinoma to the Condyle: An Unusual Case Report

Sarintip Pitwatsakul¹, Wichitsak Cholitgul², Jongkolnee Settakorn³, Uma Chotichawong¹

¹Chiang Rai Prachanukroh Hospital, Thailand

²Department of Radiology, Faculty of Dentistry, Chulalongkorn University, Thailand

³Department of Pathology, Faculty of Medicine, Chiang Mai University, Thailand

Abstract

Malignant tumors of the jawbones and metastatic tumors to the jaw are rare, while tumors metastasizing to the temporomandibular joint (TMJ) are even rarer. This report presents a case of metastatic hepatocellular carcinoma to the condyle of the TMJ in a patient with clinical symptoms mimicking TMJ dysfunction. The patient, a 55-year-old Thai male, was referred to the dentist for clarification of left TMJ pain. He was in good physical condition and reported no history of systemic diseases. He had been infected with viral hepatitis B before and had recovered well. CT images revealed a severe osteolytic lesion associated with a large soft tissue mass at the left condyle. The final diagnosis after microscopic examination was a metastatic hepatocellular carcinoma. His condition was managed with chemotherapy but he ultimately passed away 6 months later. The diagnosis of the metastatic lesion in this patient was challenging as the clinical signs and symptoms of some systemic diseases mimic those of TMJ dysfunction.

Keywords: hepatocellular carcinoma, medical CT, neoplasm metastasis, temporomandibular joint

Introduction

Malignant tumors in the oral and maxillofacial region are uncommon. Those that metastasize to the oral and maxillofacial region are even rarer, making up only 1-3% of all malignant oral neoplasms.⁽¹⁾ Metastatic lesions may occur in the oral soft tissues, jawbones, or both soft tissues and jawbones. The common primary sources of tumors metastatic to the oral and maxillofacial region are the breast, lung, and kidney. The mandible is a more common location for metastases than the maxilla, with the most commonly affected site being the molar area.⁽¹⁻⁵⁾ Frequently, malignant tumors in the oral and maxillofacial region show non-aggressive clinical findings mimicking a reactive process, benign lesions, or even simple odontogenic or non-odontogenic infections. The diagnosis of a metastatic lesion in the oral and maxillofacial region is challenging to the clinician, radiologist and pathologist. Indeed, the radiologist must identify the type of tumor through radiographic changes, while the pathologist must determine the tumor origin site.⁽⁶⁾

Generally, metastasis involves sequential progression of the primary tumor by the invasion and spreading of cancer cells through the lymphatic or blood vessels. Circulating cancer cells then settle in the microvasculature of the target organ and extravasate through the vessel wall.⁽⁶⁾ Most metastatic tumors to the oral and maxillofacial region occur in patients aged between 40 and 70 years.⁽⁷⁾ In younger patients, metastases are more common in the jawbone than in soft tissues. Gender distribution in jawbone metastases is equal, whereas the male-to-female ratio is 2:1 with regards to oral soft tissues.⁽⁸⁾ The nature of the primary tumor and sites of metastases within the oral cavity differ between the genders.^(5,9) The most common sources of metastatic tumors to the oral region are primary cancers of the lung, breast, kidney, and bone. The breast is the most common primary site for tumors that metastasize to the jawbones, whereas the lung is the most common source for cancers that metastasize to the oral soft tissues.⁽⁷⁾ A previous literature review showed that the jaw bones, particularly the mandible were more frequently affected than the oral soft tissues at a ratio of 2:1. In about 54% of cases, the attached gingiva was the most frequently affected oral soft tissue site.⁽⁸⁾ The most common primary tumor in male patients originates in the lungs, followed by tumors originating in the kidneys, prostate, liver, bone, thyroid, and skin.^(5,8,10,11) In female

patients, meanwhile, the most common primary cancers are in the breasts, followed by cancers in the genital organs, kidney, and bone.^(8,10) Few metastatic lesions to the TMJ have been reported.^(12,13) A previous study presented metastatic breast cancer in the mandibular condyle mimicking TMJ disease.⁽¹²⁾ Some case report presented TMJ metastases as a clinical manifestation of pulmonary adenocarcinoma.⁽¹⁴⁾

This case report aims to describe a metastatic lesion of liver cancer to the left condyle of the TMJ in a male patient with no history of tumor, which the initially presented with the signs and symptoms as TMJ dysfunctions that do not response to the treatment. Comprehensive examinations with oral examination, conventional and modality radiographic examinations, microscopic findings and physical re-examination, this patient was confirmed as the TMJ pain came from the metastatic lesion of the liver cancer. The establishing an exact diagnosis of metastatic lesion in the TMJ can provide a diagnostic challenge. Clinician should include the suspicion in the differential diagnosis, in particular when patient report no previous history of tumor or did not respond to the routine symptomatic treatment.

Case report

A 55-year-old Thai male patient was referred to the Dental Division, Chiang Rai Prachanukroh Hospital, Chiang Rai, Thailand for clarification of left TMJ pain and tenderness for 1-2 weeks. The pain occurred during mouth opening and the patient noticed that his signs and symptoms worsened during mastication. He did not provide information about his medical history. Extraoral examination found a maximum mouth opening of 35 to 38 mm, no clinical signs of joint deviation or deflection, and bilateral facial symmetry with normal skin intact. Pain occurred during palpation and was referred to the left pre-auricular region, ascending ramus and chin, the pain also associated with paresthesia at the medial aspect. Pain became more severe on palpation at the trigger point of the origin of the masseter muscle. There was no sign of an infection or trauma.

The intraoral examination revealed fair oral hygiene with normal oral mucosa and gingiva. There were 26 permanent teeth presented in the jaw, while teeth 18, 23, 27, 28, 38, and 43 were missing. There was generalized attrition of all of the remaining teeth without any occlusal

interference. The patient revealed later that he was treated for viral hepatitis B some years ago and had not noticed any recurrence of this viral hepatitis B. Panoramic imaging (Figure 1) revealed that all structures in the mid-facial region, including maxillary sinuses, nasal cavities, and nasal septum, were within normal limits. In the mandibular region, the left condylar head was almost destroyed. A large, diffuse osteolytic radiolucency was observed, associated with an irregular surface of the cortical bone. The internal structure of the whole mandible was characterized by generalized extensive alveolar bone resorption and the irregular bone trabecular pattern with mixed radiolucent and radiopaque appearances. The inferior border of the mandible was smooth and could be traced continuously from the left to the right side. All structures in the soft-tissue region, including the pharynx, oropharynx, nasopharynx, and hyoid bone, were within normal limits.

A dental CT was performed after the panoramic imaging, and revealed that the left condyle presented of an extensive bone destruction with an irregular bone surface of the superior and medial aspects. There was a large radiolucent mass represented of the soft tissue structure presented at the medial aspect and invaded into the bone of the left condylar head and neck (Figure 2). Moreover, medical CT imaging, performed of the head and neck region 2 weeks after the dental CT examination, revealed the extensive bone destruction and irregular bone surface in the left condyle. Most of the bone structure of the left condyle was destroyed. An irregular articular bone surface was also observed. There was a large radiopaque mass of the soft tissue structure at the masticator space closed to the medial aspect, the mass also involved into the condylar head, neck and ascending ramus. In the maxilla, the lesion also involved the posterior part of the left maxillary sinus. (Figures 3A and 3B). The 3D rendering and maximum intensity projection (MIP) images of the head and neck also revealed that the bone of the left condyle was almost destroyed and the articular bone surface was partially destroyed (Figure 4).

After the image findings, the primary malignant lesions from the TMJ and related structures such as chondrosarcoma, osteogenic sarcoma were among those of the differential diagnosis of this lesion. The metastatic lesions were also included. The patient had biopsy and microscopic examination at the Faculty of Medicine, Chiang Mai University. At this point, the tissue from the left

masticator space was taken for biopsy with core ultrasound guided needle biopsy. Microscopic examination revealed large size malignant epithelial cells arranged in thick trabeculae pattern (Figure 5A). The neoplastic cells contained oval or round shape nuclei with occasionally prominent nucleoli and abundant cytoplasm.

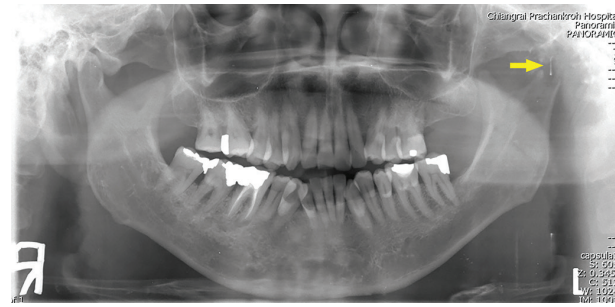


Figure 1: Panoramic image reveals severe bone destruction of the left condyle with an irregular surface and abnormal cortical bone (arrow)

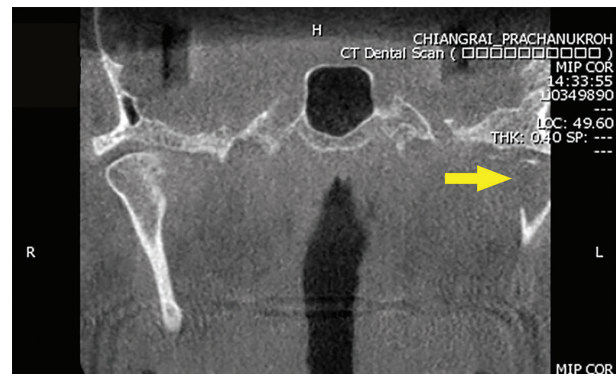


Figure 2: Dental CT image in the coronal view of the left condyle shows severe condylar bone destruction associated with bone perforation extended to the soft tissue region at the medial aspect of the ascending ramus (arrow)

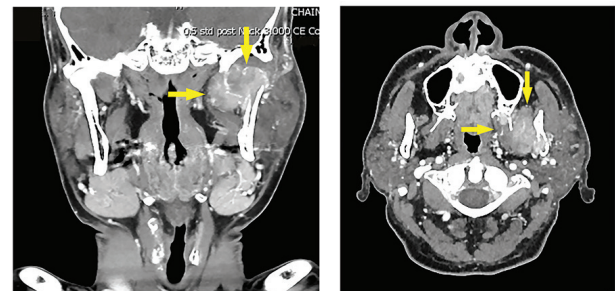


Figure 3 A

Figure 3 B

Figure 3: Medical CT images with the soft tissue window mode (3A-3B) show severe condylar bone destruction associated with a large soft tissue mass at the masticator space closed to medial aspect of the left ascending ramus (arrows)

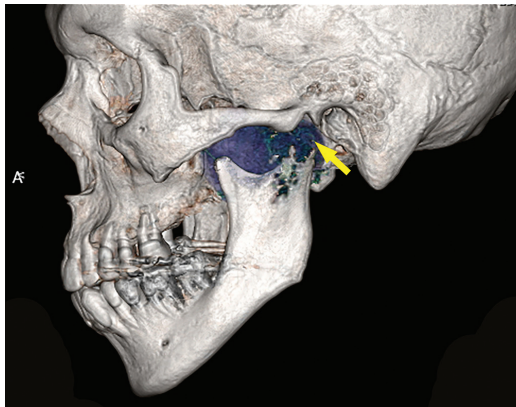


Figure 4: 3-D rendering image shows severe left condylar bone destruction (arrow)

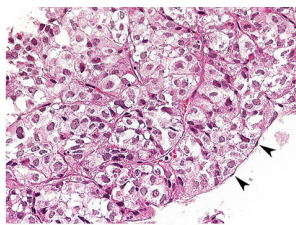


Figure 5 A

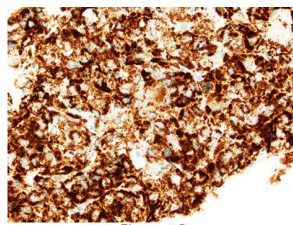


Figure 5 B

Figure 5: Microscopic features show the sections of tumor from core needle biopsy demonstrates thick trabeculae of neoplastic cells with endothelial lining (arrowheads). Red erythrocytes are noted within the narrow sinusoidal spaces between the trabeculae (Figure 5A, H&E, x400). Hepatocyte stain shows positive diffuse and strong brown granular staining pattern (Figure 5B, Hepatocyte, x400)

The cytoplasm was granular and fragile. The thick trabeculae of neoplastic cells are surrounded by endothelial cells. Immunohistochemical study using antibody to hepatocyte mitochondrial antigen (Hepatocyte, Dako Omnis, Clone OCH1E5, dilution 1:100, Ventana UltraView Universal DAB Detection Kit) showed diffuse, strong granular cytoplasmic staining (Figure 5B). Putting all this together, a final diagnosis of metastatic hepatocellular carcinoma (HCC) was reached, after which medical CT of the whole abdomen, head and neck imaging were performed to confirm the diagnosis. The CT images revealed a large HCC mass in the liver and indicated the advanced stage of the lesion. The patient was treated with periodic chemotherapy at the Faculty of Medicine, Chiang Mai University, Thailand. Oral hygiene care was provided regularly during his treatment by the dentist at Chiang Rai Prachanukroh Hospital. He passed away after 6 months of the treatment.

Discussion

Both benign and malignant tumors of the temporomandibular joint are rare and difficult to diagnose. At onset, their signs and symptoms resemble those of TMJ disorder and thus can mislead the clinical practitioner and specialist in formulating the final diagnosis. In patients who do not respond to the routine treatment, it is appropriate to reconsider the diagnosis and include the suspicion of benign or malignant tumor in the differential diagnosis.^(15,16) This case is particularly interesting because the patient presented with clinical signs and symptoms resembling those of TMJ disorders but had other subjective symptoms such as pain from the left TMJ region that was referred to the ascending ramus and which caused numbness and paresthesia at the medial aspect that are not typical of the pain experienced in TMJ disorders. However, it would have been difficult to confirm a suspicion of a defect at the left TMJ unless a panoramic image was obtained. Radiographic images showed atypical bone changes that differed from extensive degenerative temporomandibular joint disease or osteoarthritis. The typical radiographic changes of osteoarthritis include flattening of the condyle, osteophyte formation, erosion, pseudocysts, and subchondral bone sclerosis.⁽¹⁷⁾

From the panoramic image findings at the first visit, we concluded that the lesion of the left condyle was not typical of TMJ dysfunction and therefore suspected that it was a primary carcinoma. The primary malignant lesions from the TMJ and related structures were among those of the differential diagnosis of this lesion. Indeed, most primary lesions involving the temporomandibular joint are chondrosarcomas or osteogenic sarcomas. However, panoramic radiography can contribute to the early detection of maxillary/mandibular lesions, enabling the dentist to devise an appropriate treatment plan.⁽¹⁸⁾ In this case, dental CT imaging was performed after panoramic imaging to show all aspects of the left temporomandibular joint. The dental CT images revealed extensive osteolytic bone structures, including the head of the condyle. The upper part of the left ascending ramus with the medial aspect was destroyed, and there was also a soft tissue mass in this area. However, from these images, we were unable to further evaluate the soft tissue part of the left mandible, as dental CT images cannot differentiate the soft tissue in the sequence process of oral diagnostic procedures.^(19,20) Medical CT imaging was therefore performed after the

dental CT imaging and showed the details of both the hard and soft tissue changes.⁽²¹⁾ In this case, medical CT images in conjunction with microscopic examination provided more information of both primary and secondary lesions of HCC and led to complete our final diagnosis.

The pathogenesis of this metastatic lesion can be explained as a migration of the hepatocellular cells from the original lesion in the liver to extra-hepatic sites, including the lungs, regional lymph nodes, and bones (e.g., vertebrae, ribs, and long bones).^(2,5) In the oral and maxillofacial region, the mandible is the commonly affected site and, in the same way as primary HCC, metastatic HCC has a strong male predilection.⁽²²⁾ HCC can spread through the hematogenous route with concomitant lung metastasis.⁽²³⁾ Another route of spread is through the venous plexus of Batson. This is a system of valveless veins located in the epidural space between the spinal column and dura mater.⁽²⁴⁾ Malignant cells entering the plexus get lodged in the venous and sinusoidal system of bones that are connected to the venous system, thus bypassing other venous systems such as the pulmonary, canal and portal systems.

This patient was infected by viral hepatitis B some years ago, so his HCC might have developed from that infection, which accords with previous reports.^(25,26) Hepatitis B and C viruses are a global health problem, causing acute and chronic infections that can lead to liver cirrhosis and HCC. These infections are the leading cause of HCC and are associated with significant mortality. Because of its high incidence and resistance to treatment, liver cancer is the second leading cause of cancer-related death worldwide.^(25,27) The majority of viral-associated HCC cases develop in subjects with liver cirrhosis; however, hepatitis B infection can promote HCC development without prior end-stage liver disease.⁽²⁸⁾

The patient was treated through chemotherapy at the Maharaj Nakorn Chiang Mai Hospital. Early detection of metastatic cancer can affect the choice of treatment modalities and provide a better quality of life. Unfortunately, the patient's HCC was found at a late stage, resulting in the shorter survival rate than expected.

Conclusions

In conclusion, we present a case of metastatic HCC to condyle with temporomandibular disease-like symptoms, which was initially misdiagnosed at the dental clinic. The

correct diagnosis was made using a panoramic image, dental and medical CTs, and microscopic examination. The diagnosis of metastatic lesions to the oral cavity and jawbones, especially to the TMJ, is challenging to the dental clinician, oral radiologist, and pathologist because clinical signs and symptoms of certain systemic diseases mimic TMJ disorders. Consequently, the condylar metastasis cannot be defined by a single disease profile. Therefore, to diagnose it accurately is to gain a deeper understanding of the diversity of its clinical and radiographic features, meaning that comprehensive diagnosis of oral and maxillofacial dysfunction related to systemic diseases is essential.

References

1. Kumar GS, Manjunatha BS. Metastatic tumors to the jaws and oral cavity. *J Oral Maxillofac Pathol.* 2013;17:71-5.
2. Meyer I, Shklar G. Malignant tumors metastatic to the mouth and jaws. *Oral Surg Oral Med Oral Pathol.* 1965;20:350-62.
3. Nishimura Y, Yakata H, Kawasaki TT, Nakajima T. Metastatic tumors of the mouth and jaws. A review of the Japanese literature. *J Maxillofac Surg.* 1982;10:253-8.
4. Zachariades N. Neoplasms metastatic to the mouth, jaws and surrounding tissues. *J Craniomaxillofac Surg.* 1989;17:283-90.
5. Hirshberg A, Leibovich P, Buchner A. Metastatic tumors to the jawbones: analysis of 390 cases. *J Oral Pathol Med.* 1994;23:337-41.
6. Bodner L, Sion-Vardy N, Geffen DB, Nash M. Metastatic tumors to the jaws: a report of eight new cases. *Med Oral Pathol Oral Cir Bucal.* 2006;11:E132-5.
7. Van der Waal RIF, Buter J, Van der Waal I. Oral metastases: report of 24 cases. *Br J Oral Maxillofac Surg.* 2003;41:3-6.
8. Hirshberg A, Shnaiderman-Shapiro A, Kaplan I, Berger R. Metastatic tumours to the oral cavity-pathogenesis and analysis of 673 cases. *Oral Oncol.* 2008;44:743-52.
9. Rajappa S, Loya A, Rao RD. Metastasis to oral cavity: a report of two cases and review of literature. *Indian J Med Pediatr Oncol.* 2005;26:43-6.
10. Pires FR, Sagarra R, Correa ME, Pereira CM, Vargas PA, Lopes MA. Oral metastasis of a hepatocellular carcinoma. *Oral Surg Oral Med Oral Pathol Oral Radiol Endod.* 2004;97:359-68.
11. Whitaker B, Robinson K, Hewan-Lowe K, Budnick S. Thyroid metastasis to the oral soft tissues: case report of a diagnostic dilemma. *J Oral Maxillofac Surg.* 1993;51(5):588-93.
12. Chiesa AD, Scherrer B, Kuttnerberger JJ. Metastatic breast cancer in the mandibular condyle mimicking temporomandibular joint (TMJ) disease. *J Surg Case Rep.* 2014;1:rjt130.

13. Kruse ALD, Luebbbers HT, Obwegeser JA, Edelmann L, Graetz KW. Temporomandibular disorders associated with metastases to the temporomandibular joint; a review of the literature and 3 additional cases. *Oral Surg Oral Med Oral Pathol Oral Radiol Endod.* 2010;110:e21-8.
14. Boniello R, Gasparini G, Amato GD, Petrillo AD, Pelo S. TMJ metastasis: a unusual case report. *Head Face Med.* 2008;4:8.
15. Misra SR, Shankar YU, Rastogi V, Maragathavalli G. Metastatic hepatocellular carcinoma in the maxilla and mandible, an extremely rare presentation. *Contemp Clin Dent.* 2015;6(Suppl 1): S117-21.
16. Owen DG, Stelling CB. Condylar metastasis with initial presentation as TMJ syndrome. *J Oral Med.* 1985;40:198-201.
17. Gynther GW, Tronje G, Holmlund AB. Radiographic changes in the temporomandibular joint in patients with generalized osteoarthritis and rheumatoid arthritis. *Oral Surg Oral Med Oral Pathol Oral Radiol Endod.* 1996;81:613-8.
18. Im YG, Lee JS, Kim JH. Diagnostic accuracy and reliability of panoramic temporomandibular joint (TMJ) radiography to detect bony lesions in patients with TMJ osteoarthritis. *J Dent Sci.* 2018;13:396-404.
19. Jain S, Choudhary K, Nagi R, Shukla S, Kaur N. New evolution of cone-beam computed tomography in dentistry: combining digital technologies. *Imaging Sci Dent.* 2019; 49:179-90.
20. Tward DJ, Siewerdsen JH, Daly MJ, Richard S, Moseley DJ, Jaffray DA, *et al.* Soft-tissue detectability in cone-beam CT: evaluation by 2 AFC tests in relation to physical performance metrics. *Med Phys.* 2007;34(11):4459-71.
21. Wippold FJ 2nd. Head and neck imaging: the role of CT and MRI. *J Magn Reson Imaging.* 2007;25:453-65.
22. Kim JS, Kim JD. Metastatic hepatocellular carcinoma on the mandible: a case report. *Korean J Oral Maxillofac Radiol.* 2005;35:215-9.
23. Alison MR. Liver stem cells: Implications for hepatocarcinogenesis. *Stem Cell Rev.* 2005;1:253-60.
24. Batson OV. The vertebral system of veins as a means for cancer dissemination. *Prog Clin Cancer.* 1967;3:1-18.
25. Ringelhan M, McKeating JA, Protzer U. Viral hepatitis and liver cancer. *Philos Trans R Soc Lond B Biol Sci.* 2017;372(1732):20160274.
26. Du C, Feng Y, Li N, Wang K, Wang S, Gao Z. Mandibular metastasis as an initial manifestation of hepatocellular carcinoma: a report of two cases. *Oncol Lett.* 2015;9(3):1213-6.
27. Zamor PJ, deLemos AS, Russo MW. Viral hepatitis and hepatocellular carcinoma: etiology and management. *J Gastrointest Oncol.* 2017;8(2):229-42.
28. Alqahtani SA, Colombo M. Viral hepatitis as a risk factor for the development of hepatocellular carcinoma. *Hepatoma Res.* 2020;6:58.