

A Computed Tomographic Image Study on Thickness of the Modified Infrazygomatic Crest Site Between Patients with Class I and Class III Skeletal Pattern

Tonfon Damang¹, Phattaranant Mahasantipiya², Piyadanai Suteerapongpun³, Kanich Tripuwabhurut^{4,5}

¹Buddhachinaraj Phitsanulok Hospital, Thailand

²Department of Oral Biology and Diagnostic Sciences, Faculty of Dentistry, Chiang Mai University, Thailand

³Lamphun Provincial of Public Health Office, Thailand

⁴Department of Orthodontics and Pediatric Dentistry, Faculty of Dentistry, Chiang Mai University, Thailand

⁵Bigmouthten Dental Clinic, Thailand

Received: December 24, 2021 • Revised: March 11, 2022 • Accepted: April 29, 2022

Corresponding Author: Assistant Professor Dr. Kanich Tripuwabhurut, Department of Orthodontics and Pediatric Dentistry, Faculty of Dentistry, Chiang Mai University, Chiang Mai 50200, Thailand. (E-mail: kanich.t@cmu.ac.th)

Abstract

Objectives: To compare thickness of modified infrazygomatic crest (IZC) and determine an optimal area for the miniscrew insertion in modified IZCs in skeletal Class I and Class III patients.

Methods: Cone-beam computed tomography images of IZCs of 15 of skeletal Class I patients and 15 skeletal Class III patients were oriented using Dolphin Imaging software. Four axial slices were done at vertical levels of 5, 6, 7, and 8 mm apical to the buccal cemento-enamel junction of the maxillary first molar (U6). Parameters measured were buccal cortical bone thickness, buccal plate thickness of the distobuccal root of the U6 and mesiobuccal root of the maxillary second molar, and thickness of modified IZC with different angles of insertion, 55°, 60°, 65°, and 70° to the U6 occlusal plane. Independent-sample t-tests were performed ($p < 0.05$).

Results: Buccal cortical bone thickness in skeletal Class III patients (1.55±0.30 mm to 1.64±0.40 mm) was significantly greater than skeletal Class I patients (1.34±0.36 mm to 1.39±0.35 mm). Thickness of modified IZC in skeletal Class I and Class III patients showed no statistically significant differences. More than 6 mm of thickness of modified IZC were found at vertical levels of 5 and 6 mm in skeletal Class III patients and 5 mm in skeletal Class I patients.

Conclusions: Optimal areas for IZC miniscrew insertion were found at vertical levels of 5 and 6 mm in skeletal Class III patients and at vertical levels of 5 mm in skeletal Class I patients with 55°-70° insertion angles.

Keywords: buccal cortical bone thickness, Class I skeletal pattern, Class III skeletal pattern, miniscrew implant, modified infrazygomatic crest site

Introduction

Currently, miniscrews are utilized widely during orthodontic treatment. In the maxilla, the infrazygomatic crest (IZC) is one of the regions selected for miniscrew placement.^(1,2) It is a pillar of bony cortex running along the curvature between the alveolar bone and zygomatic

process of maxilla.⁽³⁾ In adults, the IZC is located above the maxillary first molar (U6). However, miniscrew placement at the IZC might injure the U6 root. As such, it is recommended that miniscrew placement be moved to the buccal bone between the distobuccal (DB) root of the U6 and the mesiobuccal (MB) root of the maxillary

second molar (U7).⁽⁴⁾ This region is called the ‘modified IZC site’, and is considered a safe zone for miniscrew placement in the maxilla.⁽⁴⁾ At present, the modified IZC site has become one of the most common regions for miniscrew placement in the maxilla, due to less chance of injuring dental roots and no hindrance to tooth movement during orthodontic treatment.

In general, modified IZC miniscrews have been used as a skeletal anchorage in patients with all types of skeletal patterns in various circumstances, e.g. entire maxillary arch distalization,⁽⁴⁾ posterior-tooth intrusion,⁽⁵⁾ and en masse retraction.⁽⁶⁾ For skeletal Class III malocclusion cases, miniscrews might play a crucial role in decompensation of maxillary anterior teeth prior to orthognathic surgery, maxillary posterior-tooth distalization for solving dental crowding, and posterior-tooth intrusion in patients with a flat occlusal plane to avoid double-jaw surgery.⁽⁷⁻¹⁰⁾

The stability of miniscrews is a critical factor affecting the success rate of orthodontic treatment,⁽¹¹⁾ while cortical bone thickness has a significant influence on miniscrew stability.^(12,13) Studies have reported that cortical bone thickness of at least 1 mm raised the miniscrew success rate.⁽¹³⁾ Miniscrew placement at the IZC 14-16 mm above the maxillary occlusal plane at an angle of 55°-70° to the maxillary occlusal plane has been suggested.⁽³⁾ Studies have reported that there are cortical bone and buccal bone thickness at the IZC in growing unilateral cleft lip and palate patients.^(14,15) Just one study has reported on the thickness of modified IZC in skeletal Class I and Class II patients⁽¹⁶⁾ and another one on IZC thickness in a growing Class III patient for miniplate placement.⁽¹⁷⁾ One study has reported IZC thickness in skeletal Class I, II and III patients.⁽¹⁸⁾ However, buccal cortical bone thickness of IZC in skeletal Class III patients has not been reported on yet.

The aims of this study were thus to compare thickness of modified IZC and determine an optimal area for the miniscrew placement for patients with skeletal Class I and Class III. In addition, we aimed to explain the basis of thickness of modified IZC in patients with skeletal Class III.

Materials and Methods

Subjects and image acquisition

This retrospective study was approved by the Human Experimentation Committee, Faculty of Dentistry, Chiang Mai University (NO.76/2020). Samples consisted of 60 Cone-beam computed tomography (CBCT) images of modified IZC regions. The images were taken from Giano (NewTom, Verona, Italy) CBCT unit. Exposure factors were set at 84 kVp, 9 mA, 11×8 cm field of view, 0.15 mm voxel size, and scanning time 18 seconds. The sample was assembled from the CBCT images of 15 skeletal Class I (ANB angle = 2° ± 2°) and 15 with skeletal Class III (ANB angle < 0°) patients who met the inclusion criteria as follows: 1) the image involved the modified IZC region; 2) full eruption of permanent dentition (except for third molar); 3) no history of orthodontic treatment; 4) no severe crowding or spacing of posterior teeth; 5) no evidence of alveolar bone loss; 6) no large metal restoration; and 7) no severe craniofacial anomalies.

Measurement of thickness of modified infrazygomatic bone

The images were oriented on all three planes before measurement, then analyzed and measured using Dolphin Imaging 11.9 (Patterson Dental Supply, Saint Paul, USA). For coronal slice orientation, the U6 occlusal plane, a plane from the MB cusp to the mesiopalatal cusp of the U6, was oriented parallel to the blue horizontal line that had been drawn automatically as a horizontal reference by the CBCT software and appeared in each coronal image slice (Figure 1A). Sagittal slice orientation, a functional occlusal plane, was oriented parallel to the blue horizontal line and the long axis of the MB root of the U6 parallel to

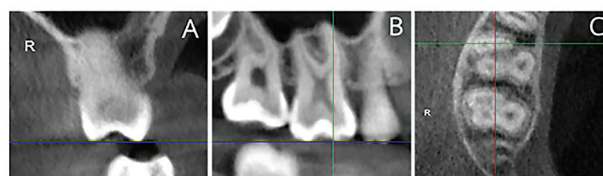


Figure 1: The images were orientated in three planes. (A) Coronal slice orientation. MB cusp, and MP cusp of the U6 were oriented parallel to the blue horizontal line. (B) Sagittal slice orientation. The long axis of the MB root of the U6 was oriented parallel to the green vertical line. (C) Axial slice orientation. Images were oriented to ensure that the green horizontal line was superimposed on the MB root of the U6.

a green vertical line that had been drawn automatically as a vertical reference by the CBCT software and appeared in each sagittal image slice (Figure 1B). For axial slice orientation, images were oriented to ensure that the green horizontal line was superimposed on the MB root of the U6 (Figure 1C).

Images were measured on four vertical levels of axial slice planes: 5, 6, 7, and 8 mm apical to the buccal cementoenamel junction (CEJ) of the U6. In the axial slice, the green vertical reference line was moved to bisect the interradicular distance between the DB root of the U6 and the MB root of the U7 (Figure 2A). Afterwards, parameters measured were buccal cortical bone thickness, which intersected with the green vertical line, buccal plate thickness at the DB root of the U6, and buccal plate thickness at the MB root of the U7 (Figure 2B). In the coronal slice, the thickness of modified IZC was measured from the buccal bone to the maxillary sinus wall at 55°, 60°, 65°, and 70°, to the U6 occlusal plane (Figure 2C).

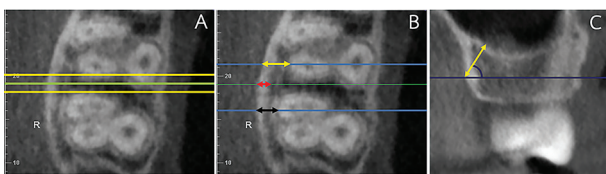


Figure 2: (A) The green vertical reference line was moved to bisect the interradicular distance. (B) Buccal cortical bone thickness (red arrow), buccal plate thickness at the DB root of the U6 (yellow arrow), and buccal plate thickness at the MB root of the U7 (black arrow) were measured. (C) Thickness of modified IZC was measured (yellow arrow).

Statistical analysis

Data herein are given as means and standard deviations, and were processed using SPSS 17.0 (IBM, Armonk, NY, USA). The intraclass correlation coefficient (ICC) were used to assess intrarater reliability, the CBCT images were re-measured by the same examiner after a four-week interval. Shapiro–Wilk test was used to verify the normal distribution of the data, Levene's test to assess equality of variance, and independent-sample t-tests to test differences in means between groups. Significance was set at $p \leq 0.05$.

Results

The data were normally distributed and showed equality in variance, with the ICC showing high intrarater reliability ($r=0.95$). There was no significant difference between thickness of the left and right modified IZC, so the left and right measurements were pooled.

Buccal cortical bone thickness

Means and standard deviations of buccal cortical bone thickness in skeletal Class I and Class III patients ranged from 1.34 ± 0.36 mm to 1.39 ± 0.35 mm and 1.55 ± 0.30 mm to 1.64 ± 0.40 mm, respectively (Table 1). At all vertical levels, buccal cortical bone thickness in skeletal Class III patients was significantly greater than skeletal Class I patients.

Buccal bone thickness

Means and standard deviations of buccal bone thickness of the DB root of the U6 and MB root of the U7 are shown in Table 2. Thickness at the DB root of the U6 at the 5, 6, and 7 mm levels in skeletal Class III patients were significantly greater than skeletal Class I patients, whereas no significant difference was found between groups at 8 mm. At the MB root of the U7, there was no significant difference in buccal bone thickness at any vertical level between skeletal Class I and Class III patients.

Thickness of modified IZC

Means and standard deviations of thickness of modified IZC are shown in Table 3. Thickness in skeletal Class I and Class III patients ranged from 4.10 ± 1.97 mm to 6.79 ± 2.01 mm and 4.41 ± 2.38 mm to 7.91 ± 2.99 mm, respectively. Rostral vertical cut levels revealed thinner modified IZC. At each combination of different vertical levels and different angles, no significant difference in thickness of modified IZC between skeletal Class I and Class III patients was found.

Discussion

This study showed that buccal cortical bone thickness at the modified IZC site in skeletal Class III patients were significantly greater than that in skeletal Class I patients, whereas there were no significant differences in thickness of modified IZCs between groups.

Primary stability of the miniscrew is the essential key to providing stationary anchorage during orthodontic

Table 1: Means and standard deviations of buccal cortical bone thickness

Vertical levels (mm)	Buccal cortical bone thickness (mm)				p
	Class I skeletal pattern		Class III skeletal pattern		
	Mean	SD	Mean	SD	
5	1.34	0.36	1.64	0.40	0.003**
6	1.36	0.47	1.61	0.40	0.034*
7	1.35	0.37	1.55	0.30	0.026*
8	1.39	0.35	1.64	0.30	0.006**

Table 2: Means and standard deviations of buccal bone thickness of the DB root of the U6 and MB root of the U7

Vertical levels (mm)	Buccal bone thickness (mm)									
	DB root of first molar					MB root of second molar				
	Class I		Class III		p	Class I		Class III		p
	Mean	SD	Mean	SD		Mean	SD	Mean	SD	
5	2.45	0.84	3.08	0.96	0.01*	2.81	0.80	2.89	0.83	0.681
6	2.36	0.94	3.03	1.07	0.01*	3.30	0.92	3.23	0.83	0.736
7	2.19	0.92	3.11	1.10	0.001**	3.73	1.12	3.64	0.93	0.736
8	2.34	1.05	3.04	1.25	0.871	4.05	1.23	4.00	0.97	0.156

Table 3: Means and standard deviations of thickness of modified IZC in skeletal Class I and Class III patients

Angle to U6 occlusal plane (°)	Vertical levels (mm)	Thickness of modified IZC (mm)				
		Class I		Class III		p
		Mean	SD	Mean	SD	
55	5	6.79	2.01	7.91	2.99	0.940
	6	5.86	2.07	6.9	2.77	0.127
	7	4.99	2.04	5.93	2.64	0.161
	8	4.16	2.01	5.00	2.49	0.161
60	5	6.63	2.11	7.60	2.73	0.105
	6	5.79	2.06	6.64	2.64	0.170
	7	4.87	2.07	5.76	2.58	0.178
	8	4.10	1.97	4.85	2.40	0.333
65	5	6.54	2.16	7.43	2.69	0.126
	6	5.75	2.04	6.57	2.57	0.146
	7	4.85	2.08	5.73	2.57	0.153
	8	4.26	2.15	4.60	2.33	0.644
70	5	6.50	2.17	7.39	2.63	0.156
	6	5.74	2.14	6.36	2.77	0.195
	7	5.03	2.16	5.32	2.7	0.555
	8	4.31	2.03	4.41	2.38	0.871

treatment, and this stability can be obtained from mechanical interlock between the thread of the implant and the surrounding bone.⁽¹⁹⁾ Moreover, the primary stability of miniscrews is also determined by several factors, including cortical bone thickness,⁽¹³⁾ bone density,⁽²⁰⁾ predrilling diameter,⁽²¹⁾ and miniscrew design, e.g. miniscrew diameter⁽²²⁾ and length.⁽²³⁾

Cortical bone thickness has been found to be a crucial factor determining the stability of miniscrews.^(1,13,24) It has been generally accepted that cortical bone thickness of at least 1 mm provides greater miniscrew stability than that of <1 mm.⁽¹³⁾ In our study, buccal cortical bone thickness in skeletal Class I and Class III patients was 1.34-1.39 mm and 1.55-1.64 mm, respectively—both >1 mm. Furthermore, buccal cortical bone thickness in skeletal Class I patients in our study was consistent with a previous study in Thai samples, which found thickness of 1.18-1.31 mm.⁽¹⁶⁾ Therefore, our findings show that cortical bone thickness at the modified IZC site in Thai skeletal Class I and skeletal Class III patients provide adequate primary miniscrew stability.

It has been suggested that 1 mm of alveolar bone between the miniscrew and dental root is required for periodontal health.^(2,25) Furthermore 1-2 mm of buccal bone at the penetration site is required to avoid injury to molar roots.^(4,16) This implies that at least 2 mm of buccal bone at the penetration site is mandatory for miniscrew placement. In our study, although buccal bone thickness at the DB root of the U6 and MB root of the U7 at all levels (5, 6, 7, and 8 mm) were >2 mm, modified IZC miniscrews should be inserted with caution to avoid injury to dental roots, particularly at the DB root of the U6 in skeletal Class I patients due to wide range of standard deviation of measurements (2.19±0.92 to 2.45±0.84 mm).

Bone thickness at the miniscrew-placement site also refers to miniscrew biting depth. Several studies have suggested that at least 6 mm of biting depth is required for miniscrew stability.^(2,3,26,27) In our study, thickness of modified IZC in skeletal Class I and III patients was 4.10-6.79 mm and 4.41-7.91, respectively. Bone thickness >6 mm was found at 5 mm apical to the CEJ in the U6 in skeletal Class I patients, and at 5 and 6 mm apical to the CEJ of the U6 in skeletal Class III patients.

Practically, miniscrew placement at the modified IZC site at 6 or 7 mm apical to the buccal CEJ of the U6 has been successfully used, although the biting depth at

these levels is <6 mm. This could be due to double cortical bone plate penetration in this implant site. The modified IZC site comprises two cortical plates, the buccal cortical bone and sinus floor.⁽³⁾ Regardless of the high incidence of maxillary sinus penetration after miniscrew placement (78.3%), the IZC miniscrew has been reported to have a success rate of 96.7%.⁽¹⁾ One study reported that <2 mm perforation at the maxillary sinus can resolve itself.⁽²⁸⁾ Limiting penetration depth to ≤1 mm has been recommended for IZC miniscrew placement. With regard to miniscrew-insertion angle, our study has revealed that a greater angle provides shallower biting depth, similar to other studies reporting that increased miniscrew-insertion angle increased the risk of maxillary sinus penetration.^(29,30) More than 6 mm of thickness of modified IZC were found at 5 mm apical to the CEJ of the U6, in skeletal Class I patients and 5 and 6 mm apical to the CEJ of the U6, in skeletal Class III patients. As such, these levels are considered to provide sufficient biting depth for miniscrew placement, while 7 and 8 mm apical to the CEJ of the U6 was questionable for miniscrew placement.

In our study, the vertical skeletal pattern factor was not included in the independent variables due to the limited sample size. One study reported that patients with hyperdivergent patterns had lower cortical bone thickness than those with normodivergent and hypodivergent patterns.⁽³¹⁾ It has been reported that a vertical skeletal pattern affects the success rate of miniscrews: a lesser Frankfort mandibular plane angle provided a greater miniscrew success rate than a greater angle.⁽³²⁾ Further research should focus on the effects of both sagittal and vertical skeletal patterns on bone thickness simultaneously.

Conclusions

Cortical bone thickness in the skeletal Class III group was greater than the skeletal Class I group. Optimal areas for IZC miniscrew insertion at 55°-70° angles were found at vertical levels of 5 and 6 mm in skeletal Class III patients and at vertical levels of 5 mm in skeletal Class I patients.

Acknowledgments

The authors would like to express their thanks to Dr. Thanapat Sastraruji, Faculty of Dentistry, Chiang Mai University for statistical consultation. This research

did not receive any specific grant or funding from funding agencies in the public, commercial, or not-for-profit sectors.

Conflicts of interest

The authors declare no conflicts of interest.

References

- Jia X, Chen X, Huang X. Influence of orthodontic mini-implant penetration of the maxillary sinus in the infrazygomatic crest region. *Am J Orthod Dentofacial Orthop.* 2018;153(5):656-61.
- Liu H, Wu X, Yang L, Ding Y. Safe zones for miniscrews in maxillary dentition distalization assessed with cone-beam computed tomography. *Am J Orthod Dentofacial Orthop.* 2017;151(3):500-6.
- Liou EJ, Chen PH, Wang YC, Lin JC. A computed tomographic image study on the thickness of the infrazygomatic crest of the maxilla and its clinical implications for miniscrew insertion. *Am J Orthod Dentofacial Orthop.* 2007;131(3):352-6.
- Lin JJ. Creative orthodontics blending the damon system & TADs to manage difficult malocclusions. Taipei, Taiwan: Yong Chieh Co.; 2010.
- Lin J, Liou E, Yeh CL. Intrusion of overerupted maxillary molars with miniscrew anchorage. *J Clin Orthod.* 2006;40:378-83.
- Liou EJW, Pai BCJ, Lin JCY. Do miniscrews remain stationary under orthodontic forces? *Am J Orthod Dentofacial Orthop.* 2004;126(1):42-7.
- Sugawara J, Nagasaka H, Yamada S, Yokota S, Takahashi T, Nanda R. The application of orthodontic miniplates to Sendai surgery first. *Semin Orthod.* 2018;24(1):17-36.
- Nagasaka H, Sugawara J, Kawamura H, Nanda R. "Surgery first" skeletal Class III correction using the skeletal anchorage system. *J Clin Orthod.* 2009;43:97-105.
- Aristizábal J, Smit R, Villegas C. The "surgery first" approach with passive self-ligating brackets for expedited treatment of skeletal Class III malocclusion. *J Clin Orthod.* 2015;49:361-9.
- Park HS, Kim JY, Kwon TG. Occlusal plane change after intrusion of maxillary posterior teeth by microimplants to avoid maxillary surgery with skeletal Class III orthognathic surgery. *Am J Orthod Dentofacial Orthop.* 2010;138(5):631-40.
- Tseng YC, Pan CY, Liu PH, Yang YH, Chang HP, Chen CM. Resonance frequency analysis of miniscrew implant stability. *J Oral Sci.* 2018;60(1):64-9.
- Farnsworth D, Rossouw PE, Ceen RF, Buschang PH. Cortical bone thickness at common miniscrew implant placement sites. *Am J Orthod Dentofacial Orthop.* 2011;139(4):495-503.
- Motoyoshi M, Yoshida T, Ono A, Shimizu N. Effect of cortical bone thickness and implant placement torque on stability of orthodontic mini-implant. *Int J Oral Maxillofac Implants.* 2006;22:779-84.
- Trirattanapradit C, Chaiworawitkul M. Buccal bone thickness at infrazygomatic crest site in thai growing unilateral cleft lip and palate patients. *CM Dent J.* 2019;40(2):29-37.
- Trirattanapradit C, Thongvigitmanee S, Chaiworawitkul M. Comparison of the buccal cortical bone thickness in growing thai patients with unilateral cleft lip and palate using cone-beam computed tomography. *CM Dent J.* 2019;40(3):81-9.
- Lohalerkit C, Poolsin K, Janhom A, Patanaporn V, Jotikasthira D. Comparison of infrazygomatic crest thicknesses between Thai patients with Class I and Class II skeletal pattern using cone beam computed tomography. *Thai Assoc Orthod.* 2018;8(1):3-12.
- Lee HS, Choi HM, Choi DS, Jang I, Cha BK. Bone thickness of the infrazygomatic crest area in skeletal Class III growing patients: a computed tomographic study. *Imaging Sci Dent.* 2013;43(4):261-6.
- Tavares A, Crusóé-Rebello IM, Neves FS. Tomographic evaluation of infrazygomatic crest for orthodontic anchorage in different vertical and sagittal skeletal patterns. *J Clin Exp Dent.* 2020;12(11):e1015-e20.
- Araghbidikashani M, Golshah A, Nikkardar N, Rezaei M. *In vitro* impact of insertion angle on primary stability of miniscrews. *Am J Orthod Dentofacial Orthop.* 2016;150(3):436-43.
- Holm L, Cunningham SJ, Petrie A, Cousley RR. An *in vitro* study of factors affecting the primary stability of orthodontic mini-implants. *Angle Orthod.* 2012;82(6):1022-8.
- Phusantisampan P, Jotikasthira D, Jariyapongpaiboon P, Tripuwabhut K. Effects of pre-drilled pilot-hole diameters on miniscrew implant primary stability: an *in vitro* study. *CM Dent J.* 2020;41(3):13-22.
- Lim SA, Cha JY, Hwang CJ. Insertion torque of orthodontic miniscrews according to changes in shape, diameter and length. *Angle Orthod.* 2008;78(2):234-40.
- Damang T, Tripuwabhut K, Jotikasthira D. Effects of stainless steel miniscrew length on primary stability: an *in vitro* study. *CM Dent J.* 2020;41(3):23-30.
- Motoyoshi M, Inaba M, Ono A, Ueno S, Shimizu N. The effect of cortical bone thickness on the stability of orthodontic mini-implants and on the stress distribution in surrounding bone. *Int J Oral Maxillofac Surg.* 2009;38(1):13-8.
- Poggio P, Incorvati C, Velo S, Carano A. "Safe zones": A guide for miniscrew positioning in the maxillary and mandibular arch. *Angle Orthod.* 2006;76:191-7.
- Melsen B, Costa A. Immediate loading of implants used for orthodontic anchorage. *Clin Orthod Res.* 2000;3(1):23-8.

27. Wehrbein H, Glatzmaier J, Yildirim M. Orthodontic anchorage capacity of short titanium screw implants in the maxilla. an experimental study in the dog. *Clin Oral Implants Res.* 1997;8(2):131-41.
28. Ardekian L, Oved-Peleg E, Mactei EE, Peled M. The clinical significance of sinus membrane perforation during augmentation of the maxillary sinus. *J Oral Maxillofac Surg.* 2006;64(2):277-82.
29. Laursen MG, Melsen B, Cattaneo PM. An evaluation of insertion sites for mini-implants: a micro-CT study of human autopsy material. *Angle Orthod.* 2013;83(2):222-9.
30. Baumgaertel S, Hans MG. Assessment of infrazygomatic bone depth for mini-screw insertion. *Clin Oral Implants Res.* 2009;20(6):638-42.
31. Costa JVD, Ramos AL, Iwaki Filho L. Zygomatic-maxillary cortical bone thickness in hyper, normo and hypodivergent patients. *Dental Press J Orthod.* 2021;26(1):e211965.
32. Moon CH, Park HK, Nam JS, Im JS, Baek SH. Relationship between vertical skeletal pattern and success rate of orthodontic mini-implants. *Am J Orthod Dentofacial Orthop.* 2010;138(1):51-7.