

# A Morphometric Study of the Root Concavity on the Extracted First Premolar in a Group of the Thai Population

Kunyamon La-orkhun<sup>1</sup>, Pineekan Lapanun<sup>1</sup>

<sup>1</sup>Department of Conservative Dentistry, Faculty of Dentistry, Western University, Thailand

Received: June 17, 2020 • Revised: September 16, 2021 • Accepted: September 20, 2021

Corresponding Author: **Dr. Kunyamon La-orkhun**, Department of Conservative Dentistry, Faculty of Dentistry, Western University, Bangkok 10110, Thailand. (E-mail: [kunyamon@hotmail.com](mailto:kunyamon@hotmail.com))

## Abstract

**Objectives:** The objective of this research was to determine the average concavity depth and width of first premolars in a group of Thais compared to the size of instruments used in periodontal therapy.

**Methods:** Among 260 extracted first premolars, 130 were maxillary and the other 130 mandibular. The width and depth of root concavities were measured at the coronal third and middle third with a surface-roughness tester. The width of the periodontal instruments was measured with Vernier calipers.

**Results:** Means and standard deviations of the concavity depth of the maxillary first premolar at the coronal third of mesial aspects, middle third of mesial aspects, coronal third of distal aspects, and middle third of distal aspects were 0.765±0.221 mm, 0.711±0.278 mm, 0.314±0.223 mm, and 0.504±0.250 mm, respectively. For the mandibular first premolar at the coronal third of mesial aspects, middle third of mesial aspects, coronal third of distal aspects, and middle third of distal aspects, values were 0.165±0.169 mm, 0.201±0.186 mm, 0.125±0.141 mm, and 0.139±0.132 mm, respectively. Means and standard deviations of the concavity width of the maxillary first premolar at the mesial and distal aspects were 0.836±0.607 mm and 1.874±0.976 mm, respectively, while for the mandibular first premolar at the mesial and distal aspects, values were 1.848±0.392 mm and 2.136±0.545 mm, respectively. The working-end widths of the instruments were 0.418–0.840 mm, and 18.46% of the mesial aspects of maxillary premolars were narrower than the smallest width of the instrument.

**Conclusions:** Based on this study, information on root concavities in first premolars in the Thai population will assist in better evaluation and treatment planning concerning the limited accessibility of instrumentation for use in root concavities, which can affect periodontal treatment outcomes.

**Keywords:** first premolar, root concavity, Thai

## Introduction

Periodontitis is an infectious disease and chronic inflammatory condition affecting the periodontium caused by bacterial plaque. There are local factors involved in periodontitis, such as calculus, crowding of teeth, and cervical caries, and anatomic factors that appear differently in each person, such as cervical enamel projection, enamel pearl, or palatogingival groove. This includes the morphology of teeth, which varies from person to

person. Different types of tooth morphology have different responses to treatment. Some types of tooth morphology increase the chances of more bacteria deposits,<sup>(1)</sup> so being able to identify the type of tooth morphology can enhance diagnosis and periodontitis therapy.<sup>(2)</sup>

Although there has been a study on root morphology of the first premolar<sup>(3)</sup> in a group of Thais, the incidence of root concavity in the first premolar is still unknown. From a study on a group of Indians by Joseph *et al.*,<sup>(2)</sup>

it was reported that 100 maxillary first premolars had average concavity depths of the maxillary first premolar at the coronal third of mesial aspects, middle third of mesial aspects, coronal third of distal aspects, and middle third of distal aspects of  $0.77\pm 0.49$  mm,  $0.74\pm 0.59$  mm,  $0.32\pm 0.42$  mm, and  $0.67\pm 0.69$  mm, respectively, while 63% of all teeth involved had fused roots and 37% separated roots. Concavities at the mesial aspect were deeper than those at the distal aspect. Fox and Bosworth<sup>(4)</sup> studied 108 Americans' first premolars and discovered that 100% of maxillary first premolars and 92% of mandibular first premolars had concavity. This *in vitro* study showed that the prevalence of root concavities in the maxillary first premolar had a statistically significantly greater loss of attachment on the concavity than on the nonconcavity surface. Zhao *et al.*<sup>(5)</sup> reported that in Chinese people, the incidence of mesial and distal root concavities in the maxillary first premolar was 100% and 39.3%, respectively, and in the mandibula, incidence was 42.5% and 31.3%, respectively. On the basis of the evidence from these two studies, root concavities in Chinese and Americans are different. Therefore, the incidence of root concavities in Thais might be different too. Root concavities accompanied by gingival recession and periodontitis also make it difficult to remove plaque in this area. When calculus occurs, patients who find difficulty in removing calculus by themselves need scaling and root planing by a dentist. Currently, there are efficient instruments for root planing, such as the piezoelectric ultrasonic scalers and Gracey curettes, but the average width and depth of first premolar concavities in Thais is still unknown. The objective of this study was to determine the average concavity depth and width of first premolars in a group of Thais compared to the size of instruments used in periodontal therapy, in order to choose proper and effective instruments.

## Materials and Methods

A total of 260 extracted teeth were divided into 130 maxillary first premolars and 130 mandibular first premolars. The teeth were soaked in a 10% formalin solution following collection. After washing, they were soaked in a 3% concentrated sodium hypochlorite solution for 3 hours to loosen attached soft tissue.

The remaining calculus and soft tissue were removed carefully using an ultrasonic scaler to avoid damaging the root surface. The teeth were taken for measurement of

root concavities by the same measurer. Then, width was measured at 1 mm below the beginning of the concavity, because this was where it could be considered wide enough for measurement and is conveniently located near the cervical area, where periodontitis patients required scaling and root planing. Depth was also measured at the deepest position along the length of the root concavity, but only near the cervical third and the middle third of the root. The apical third of the root was not measured, because these teeth were often extracted in cases of periodontitis. The width and depth of the root concavities were measured with a surface-roughness tester (Figure 1), and the results are displayed in Figure 2 in which the distance from A to B parallel to the x-axis is the width of the root concavity, and the distance from line AB to C parallel to the y-axis is the depth of the root concavity. Value are given to three decimal places, and measurement was performed twice, 10 minutes apart. If the difference exceeded 0.1 mm, the measurement was retaken, as an error might have occurred. After that, the average of the two measurements was calculated. Widths of the unused scaling and root-planing instruments were measured at 1 mm apart at the tip. Measurements were taken from 10 instruments of each type to calculate the average width using Vernier calipers as follows:

1. Gracey curette 13/14 (Hu-Friedy, Chicago, USA),
2. Gracey curette 15/16 (Hu-Friedy, Chicago, USA),
3. EMS<sup>TM</sup> Perio Slim (Electro Medical Systems, Nyon, Switzerland),
4. H2R, H2L<sup>TM</sup> tip (Acteon, La Ciotat, France).

## Data analyses

Arithmetic means and standard deviations of depth and width were used for data analysis of the first premolar and used to calculate the number of first premolar concavities that were narrower than the ultrasonic scaler and manual curette in terms of a percentage.

## Results

The incidence of mesial and distal root concavities of the maxillary first premolar was 100% and 96%, respectively, and in mandibular premolars 82% and 91%, respectively (Table 1).

Means and standard deviations of the concavity depth of the maxillary first premolar at the coronal third of mesial aspects, middle third of mesial aspects, coronal

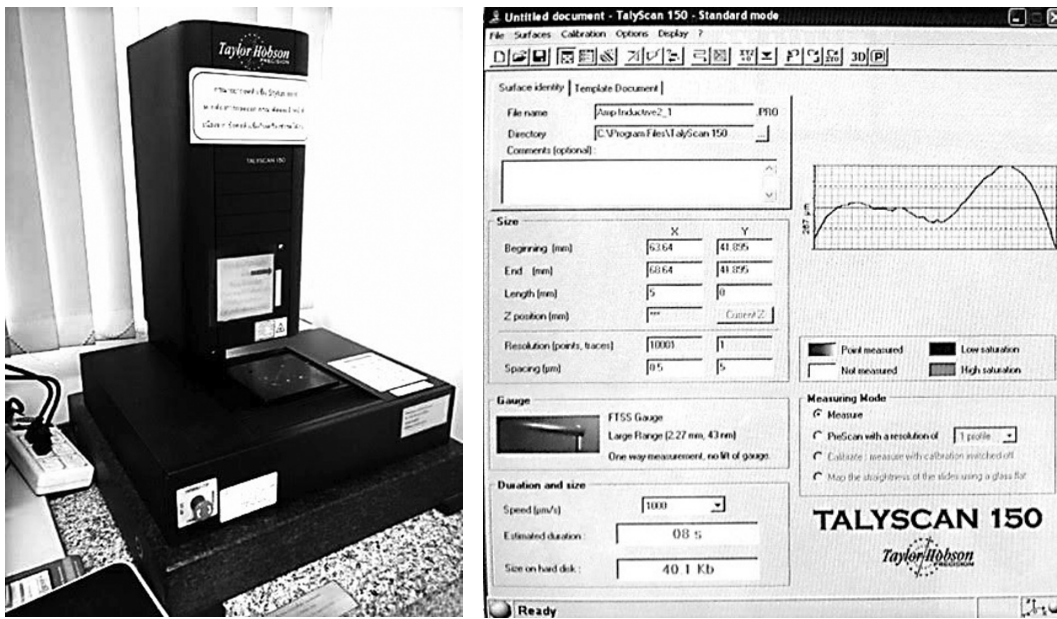


Figure 1: Surface roughness tester showing the processing connected with the computer.

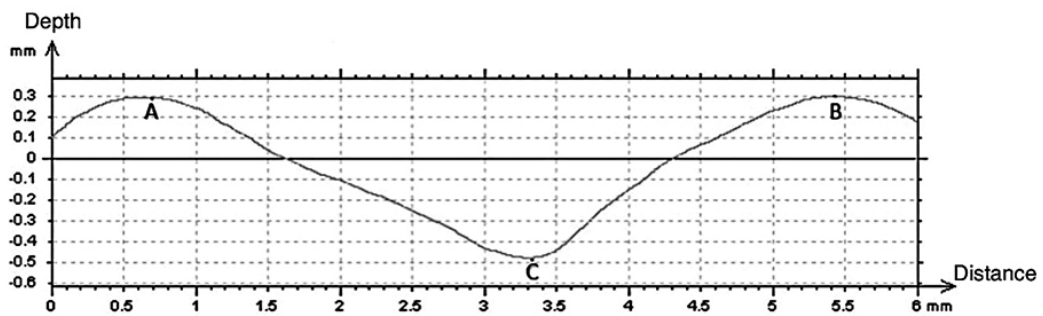


Figure 2: Graph showing the results of the measurement of the root concavity of the first premolar.

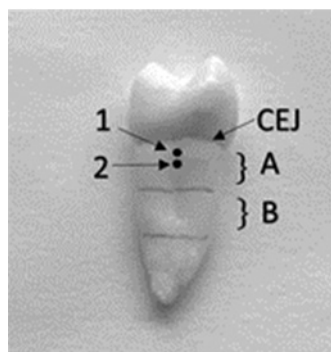


Figure 3: The locations where the root concavity was measured.

CEJ: Cementoenamel junction.

Point 1: The start point of the root concavity.

Point 2: The point measured for the width of the root concavity was 1mm below the start point.

A: The deepest root concavity depth was measured at the coronal third zone.

B: The deepest root concavity depth was measured at the middle third zone.

third of distal aspects, and middle third of distal aspects were  $0.765\pm 0.221$  mm,  $0.711\pm 0.278$  mm,  $0.314\pm 0.223$  mm, and  $0.504\pm 0.250$  mm respectively (Table 2). For mandibular first premolars at the coronal third of mesial aspects, middle third of mesial aspects, coronal third of distal aspects, and middle third of distal aspects, values were  $0.165\pm 0.169$  mm,  $0.201\pm 0.186$  mm,  $0.125\pm 0.141$  mm, and  $0.139\pm 0.132$  mm, respectively (Table 3). Means and standard deviations of concavity widths of the maxillary first premolar at the mesial and distal aspects were  $0.836\pm 0.607$  mm and  $1.874\pm 0.976$  mm, respectively, and for mandibular first premolars at the mesial and distal aspects, widths were  $1.848\pm 0.392$  mm and  $2.136\pm 0.545$ , mm, respectively.

Average width of the Gracey curette 13/14 measured at 1 mm from the tip was  $0.826\pm 0.038$  mm, and the 15/16 was  $0.840\pm 0.039$  mm. Average width of the Perio Slim tip measured at 1 mm from the tip was  $0.627\pm 0.030$  mm, and the piezoelectric H2R H2L tip was  $0.418\pm 0.035$  mm (Table 4). Mean concavity widths of first premolars of  $<0.418$  mm and  $<0.826$  mm made them inaccessible for the tip of the piezoelectric ultrasonic scaler and Gracey curette, respectively. First premolar concavity width narrower than the smallest width of the piezoelectric ultrasonic scaler ( $<0.418$  mm) was found only in the case of the mesial aspect of the maxillary first premolar in 24 of the 130 teeth (18.46%). Mean concavity width of the first premolar was narrower than the smallest width of the Gracey curette ( $<0.826$  mm) at the mesial aspect of the maxillary first premolar in about 44 of the 130 teeth (33.85%), while the distal aspect of the maxillary first premolar was narrower in about 25 of the 130 teeth (19.23%). There were no mandibular first premolars for which the width of the root concavity was less than the width of most instruments currently in use (Table 5).

## Discussion

It was found that root concavities in the Thai population were present in 96%-100% of maxillary first premolars and 82%-91% of mandibular first premolars (Table 1). These figures are different from American<sup>(4)</sup> and Chinese<sup>(5)</sup> populations, which may be due to ethnic differences. Several studies<sup>(5-7)</sup> have found root concavities at the mesial aspect of the maxillary first premolar to be 100%. The reason for this concavity in all these areas is because it is a characteristic of the maxillary first pre-

**Table 1:** The percentage of the concavity of the first premolar.

Tooth type	Mesial concavity	Distal concavity
Maxillary first premolar	100%	96%
Mandibular first premolar	82%	91%

**Table 2:** Mean values and standard deviations (SD) of the depth of the root concavity in the maxillary first premolar.

Maxillary first premolar	Mean±SD (mm)
<b>Mesial depth</b>	
Cervical third	0.765±0.221
Middle third	0.711±0.278
<b>Distal depth</b>	
Cervical third	0.314±0.223
Middle third	0.504±0.250

**Table 3:** Mean values and standard deviations (SD) of the depth of the root concavity in the mandibular first premolar.

Mandibular first premolar	Mean±SD (mm)
<b>Mesial depth</b>	
Cervical third	0.165±0.169
Middle third	0.201±0.186
<b>Distal depth</b>	
Cervical third	0.125±0.141
Middle third	0.139±0.132

**Table 4:** Mean values and standard deviations (SD) of the blade face widths of the curette at one millimeter from the tip.

Blade face widths of curette	Mean±SD (mm)
Gracey curette 13/14 (Hu-Friedy Co., Chicago, USA)	0.826±0.038
Gracey curette 15/16 (Hu-Friedy Co., Chicago, USA)	0.840±0.039
EMS™ Perio Slim (Electro Medical system, Nyon, Switzerland)	0.627±0.030
H2R,H2L™ tips (Acteon, La Ciotat, France)	0.418±0.035

**Table 5:** The percentage of the concavity width of maxillary first premolar  $<0.418$  mm and  $<0.826$  mm.

First premolar	Concavity width	<0.418 mm (%)	<0.826 mm (%)
Maxillary	Mesial	18.64	33.85
	Distal	0	19.23
Mandibular	Mesial	0	0
	Distal	0	0

molar, in which the mesial developmental depression, or canine fossa, is found. In the Thai population, concavities on the root surface are found in as many as 82%-100% of all first premolars, and several studies have found that root concavities in the first premolar are associated with periodontitis. For example, Fox *et al.*<sup>(4)</sup> examined 108 extracted first premolars with periodontitis to study the incidence of root concavities. Before tooth extraction, measurements of the probing depth and gingivitis index were taken for all teeth and radiography conducted. The incidence of root concavity was 100% in the maxillary first premolar and 92% in the mandibular first premolar. *In vitro* examinations showed that first premolars with root concavities had statistically significantly greater attachment loss than in those that lacked root concavities. In addition, Zhao *et al.*<sup>(5)</sup> collected 272 first premolars from 99 patients with periodontitis. Root morphology was examined with cone beam computed tomography to determine root surfaces and types of bone defects from the mesial and distal aspects of the root. To evaluate the significance of first premolar root concavities on clinical indices of chronic periodontal disease and alveolar bone defects, it was found that the mean probing depth and clinical attachment loss of the first premolars with concavities were statistically significantly higher than those without concavities. In addition, plaque accumulation was significantly different between first premolars with concavities and those without, whereby first premolars with root concavities showed greater plaque accumulation than those without. Therefore, root concavity may be an important contributor to local periodontal disease of the first premolar. As a result, it is important to focus on the treatment of first premolars that have concavities of the root.

The method of measuring the depth of the concavity in each study was different. Joseph *et al.*<sup>(2)</sup> used a dial gauge for measuring the depth of root concavities of the first premolar. This dial gauge can be used to measure length and depth. It has clock-like dials and scales on which each increment is 0.01 mm, and it is often used to measure work equipment according to production standards. It can also be used as a comparative measuring device. As such, it is used to set the root surface plane and concavity depth compared to the root surface plane. It can measure the depth of root concavities to two decimal places. However, in this study, a surface-roughness tester was

used to measure the depth of first premolar concavities. This device measures the depth of an object by measuring the ideal surface deviation against the actual surface. If the deviation is large, then it is very rough. If the deviation is small, then there is less roughness. Measurement resolution is to three decimal places. Due to the use of different measurement devices for each study, different mean premolar concavity depths may be obtained.

In this study, the mean mesial concavity depth of the first premolar was found to be greater than the distal depth of the first premolar, similar to other studies,<sup>(2,8)</sup> where the mean greatest depth was found at the mesial root of the first premolar on two fused roots with narrow and deep concavities. This concavity has been studied in terms of root grooves<sup>(9)</sup> or mesial developmental grooves. In addition, the concavity width of the maxillary first premolar at the mesial aspect was lower than the smallest instrument (<0.418 mm) in 24 of 130 teeth, accounting for 18.46% of all first premolars (Table 5). This feature was narrower than the tip size of conventional root-planing instruments, such as ultrasonic scalers or Gracey curettes. These narrow root concavities cannot be cleaned by those instruments. In addition, the concavities are located between the teeth, making it difficult for patients to clean when suffering from periodontitis. Therefore, treatment with a small-tipped instrument is recommended in this narrow concavity area. At present, scalers and root-planing instruments are being developed to be much smaller, such as piezoelectric ultrasonic diamond-tip instruments (H2R and H2L), which are only 0.418 mm in size. However, caution should be exercised in using a small-tipped tool with a rotating diamond point, as Leknes *et al.*<sup>(11)</sup> found that periodontitis pathogens could be deposited on the rough root surface after root planing. The roots treated with a rotating diamond point were significantly rougher than root surfaces treated by a manual curette. Therefore, it is recommended that ultrasonic instruments not be used alone, but in conjunction with a handheld instrument. However, root concavity of the premolar is effective for periodontitis when the loss of alveolar bone occurs between the teeth. It can easily cause plaque to build up around the concavity and become difficult to clean. Matthew *et al.*<sup>(12)</sup> found that when the maxillary first premolar developed periodontitis and loss of alveolar bone, there was the potential for dental plaque to easily build up at this root concavity. Smukler *et al.*<sup>(13)</sup> found that the area

between the teeth was difficult to clean when periodontitis occurred. Therefore, a comparative study of the effectiveness of devices for cleaning between the teeth at the root concavity was conducted. The following instruments were studied: floss, interdental brush, toothpick, and superfloss. It was concluded that the interdental brush was the most effective instrument for cleaning this area. Therefore, it is recommended that patients with periodontitis clean these concavities with an interdental brush so that the bristles between the teeth can help clean the concavity area better.

## Conclusions

The incidence of concavities in the first premolar in the Thai population and the mean depth of concavities from this study will assist in offering better evaluation and treatment planning in the Thai population, as well as choosing a suitably sized instrument for the treatment of periodontal disease of the first premolar.

## Acknowledgments

Thanks are extended to Western University for the research funding, and to the staff and students of the Department of Conservation Dentistry, Western University School of Dentistry for their support in facilitating data collection.

## Conflicts of interest

The authors declare no conflicts of interest.

## References

1. Gu YC. A micro-computed tomographic analysis of maxillary lateral incisors with radicular grooves. *J Endod.* 2011;37:789-92.
2. Joseph I, Verma BR, Bhat KM. Clinical significance of furcation anatomy of the maxillary first premolar: a biometric study on extracted teeth. *J Periodontol.* 1996;67:386-9.
3. Suknipa W. *Dental Anatomy*, 1<sup>st</sup> ed. Chulalongkorn University Bookcentre; 1993:24-34 (in Thai).
4. Fox SC, Bosworth BL. A morphological survey of proximal root concavities: a consideration in periodontal therapy. *J Am Dent Assoc.* 1987;114:811-4.
5. Zhao H, Wang H, Pan Y, Pan C, Jin X. The relationship between root concavities in first premolars and chronic periodontitis. *J Periodont Res.* 2014;49:213-9.
6. Booker BW, Loughlin DM. A morphologic study of the mesial root surface of the adolescent maxillary first bicuspid. *J Periodontol.* 1985;56:666-70.
7. Bhavya B, Vineeta Shaji. The relationship between root concavities in premolars and mandibular molars and chronic periodontitis: a tomographic study. *Int J Contemp Med Res.* 2017;4:1728-32.
8. Gher ME, Vernino AR. Root morphology - clinical significance in pathogenesis and treatment of periodontal disease. *J Am Dent Assoc.* 1980;101:627-33.
9. Leknes KN, Lie T, Wikesjo UME, Selvig KA. Root grooves: a risk factor in periodontal attachment loss. *J Periodontol.* 1994;65:859-63.
10. Rashmi GS Phulari. *Dental anatomy physiology and occlusion 2<sup>nd</sup> edition*, India: Jaypee Brothers Medical Publishers; 2019.
11. Leknes KN, Lie T, Wikesjo UME, Bogle GC, Selvig KA. Influence of tooth instrumentation roughness on subgingival microbial colonization. *J Periodontol.* 1994;65:303-8.
12. Matthews DC, Tabesh M. Detection of localized tooth-related factors that predispose to periodontal infections. *Periodontol 2000.* 2004;34:136-50.
13. Smukler H, Nager MC, Tolmis PC. Interproximal tooth morphology and its effect on plaque removal. *Quintessence Int.* 1989;20:249-55.