

ผลของซีเมนต์ชั่วคราวที่มียูจีนอลเป็นส่วนประกอบต่อ การไหลเวียนโลหิตของเนื้อเยื่อในภายหลังการกรอฟันเต็มซี่ Effect of Eugenol-containing Temporary Cement on Pulpal Blood Flow after Full Crown Preparation

มาริสสา สุขพัทธ์¹, สิทธิชัย วนจันทรรักษ์², วริศรา ศิริมหาราช³

¹ภาควิชาทันตกรรมประดิษฐ์ คณะทันตแพทยศาสตร์ มหาวิทยาลัยเชียงใหม่

²ภาควิชาชีววิทยาช่องปากและวิทยาการวินิจฉัยโรคช่องปาก คณะทันตแพทยศาสตร์ มหาวิทยาลัยเชียงใหม่

³ภาควิชาทันตกรรมจัดฟันและทันตกรรมสำหรับเด็ก คณะทันตแพทยศาสตร์ มหาวิทยาลัยเชียงใหม่

Marisa Sukapattee¹, Sitthichai Wanachantararak², Varisara Sirimaharaj³

¹Department of Prosthodontics, Faculty of Dentistry, Chiang Mai University

²Department of Oral Biology and Oral Diagnostic Sciences, Faculty of Dentistry, Chiang Mai University

³Department of Orthodontics and Pediatric Dentistry, Faculty of Dentistry, Chiang Mai University

ชม. ทันตสาร 2560; 38(1) : 93-100

CM Dent J 2017; 38(1) : 93-100

บทคัดย่อ

วัตถุประสงค์: เพื่อดูผลของซีเมนต์ชั่วคราวที่มียูจีนอลเป็นส่วนประกอบต่อการไหลเวียนโลหิตของเนื้อเยื่อใน (พีบีเอฟ) ภายหลังการกรอฟันเต็มซี่ในมนุษย์

วัสดุและวิธีการทดลอง: การทดลองนี้ทำในฟันกรามน้อยล่างซี่ที่สองจำนวน 20 ซี่ที่มีการกรอเตรียมเพื่อเป็นฟันหลักของสะพานฟันติดแน่น การกรอเตรียมฟันทำโดยใช้ด้ามกรอความเร็วสูงที่มีน้ำพ่นภายใต้การฉีดยาชาเฉพาะที่ยึดสะพานฟันชั่วคราวด้วยซีเมนต์ชั่วคราวที่มียูจีนอลเป็นส่วนประกอบในกลุ่มที่ 1 และไม่มียูจีนอลเป็นส่วนประกอบในกลุ่มที่ 2 บันทึกค่าพีบีเอฟด้วยเครื่องเลเซอร์ดอปเพลอร์โพลาร์มิเตอร์ภายหลังการกรอแต่งฟันสมบูรณ์ (วันที่ 0)

Abstract

Objective: To determine the effect of eugenol-containing temporary cement on pulpal blood flow (PBF) after full crown preparation in human subjects.

Materials and Methods: The experiments were carried out on 20 mandibular second premolars prepared for abutments of fixed bridges. Crown preparation was made using an air-rotor hand-piece with water-spray under local anesthesia. The temporary bridges were cemented with eugenol-containing temporary cement (Group

Corresponding Author:

สิทธิชัย วนจันทรรักษ์

รองศาสตราจารย์ ทันตแพทย์ ดร., ภาควิชาชีววิทยาช่องปาก
และวิทยาการวินิจฉัยโรคช่องปาก คณะทันตแพทยศาสตร์
มหาวิทยาลัยเชียงใหม่

Sitthichai Wanachantararak

Assoc. Prof. Dr., Department of Oral Biology and Oral Diagnostic Sciences, Faculty of Dentistry, Chiang Mai University
E-mail: sitthichai.w@cmu.ac.th

และหลังจากยึดซีเมนต์ชั่วคราว 1 วัน (วันที่ 1) และ 7 วัน (วันที่ 7) นำข้อมูลวันที่ 0 มาปรับให้เป็น 100 เพื่อสร้างข้อมูลทั้งสองกลุ่มให้มีความเท่ากัน

ผลการทดลอง: ในกลุ่มที่ 2 ค่าพีบีเอฟที่ปรับแล้วที่บันทึกได้ในวันที่ 7 มีค่าสูงกว่าในวันที่ 1 และวันที่ 0 อย่างมีนัยสำคัญทางสถิติ ($p < 0.05$) โดยใช้สถิติการวิเคราะห์ความแปรปรวนแบบสองทางเมื่อมีการวัดซ้ำ ค่าพีบีเอฟที่ปรับแล้วที่บันทึกได้ในวันที่ 7 ในกลุ่มที่ 2 มีค่าสูงกว่าในกลุ่มที่ 1 อย่างมีนัยสำคัญทางสถิติ แต่ไม่มีความแตกต่างกันอย่างมีนัยสำคัญทางสถิติของค่าที่ได้ในแต่ละสภาวะของกลุ่มที่ 1

สรุป: ไม่มีการเปลี่ยนแปลงของการไหลเวียนโลหิตของเนื้อเยื่อในหลังจากการยึดซีเมนต์ชั่วคราวที่มียูจีนอลเป็นส่วนประกอบภายในระยะเวลา 1 สัปดาห์ แสดงให้เห็นว่าไม่พบการอักเสบเกิดขึ้น

คำสำคัญ: ยูจีนอล การไหลเวียนโลหิตของเนื้อเยื่อใน เลเซอร์-ดอปเพลอร์โฟลว์มิเตอร์ การกรอเตรียมฟัน

I) or non-eugenol temporary cement (Group II). PBF was recorded with a laser Doppler flow meter (LDF) after complete crown preparation (day 0), one day (day 1) and seven days (day 7) after temporary cementation. The data were normalized to 100 to produce baseline values.

Results: In Group II, the adjusted PBF values recorded on day 7 were significantly higher than those on day 1 and day 0 ($p < 0.05$, Two-way RM ANOVA). The adjusted PBF values recorded on day 7 in Group II were significantly higher than those in Group I. No significant differences were found between each condition in Group I.

Conclusions: There was no change in pulpal blood flow within a week when cementation was with eugenol-containing temporary cement, indicating that no pulpal inflammation was observed.

Keywords: eugenol, pulpal blood flow, laser Doppler flow meter, tooth preparation

Introduction

Abutment preparation in fixed prosthodontics procedures using dental burs in an airtor hand-piece causes more severe pulp reactions than other operative procedures, because more dentinal tubules are exposed. Those prepared teeth need to be covered with a provisional restoration during fabrication of the final prosthesis. Temporary cement is used for bonding the provisional prosthesis to the tooth structure. It prevents leakage of saliva and bacteria from outside into the dentine and the dental pulp and reduces pulpal injury from tooth preparation. Some types of temporary cement contain eugenol that has bactericidal and sedative effects. When used in low concentration, eugenol is slowly released into dentine and reduces dentine sensitivity and pulpal

inflammation from tooth preparation procedures.⁽¹⁾

On the other hand, eugenol can irritate the pulp when applied directly on the exposed thin remaining dentine. When dentine thickness is less than 0.5 mm, eugenol is released faster than with thick dentine.^(1,2)

One of the disadvantages of eugenol is that it inhibits resin polymerization of resin cement and decreases bond strength between the restorations and the tooth structure.⁽³⁾ For this reason, most dentists avoid using temporary cement with eugenol when they plan to use resin cement to bond final restorations; thus the sedative effect of eugenol cannot be expected. The responses of dental pulp to dental procedures or dental materials can be determined by monitoring pulpal blood flow using a Laser Doppler flow (LDF) meter.^(4,5) This is a non-invasive

technique suitable for monitoring changes in blood circulation in *vivo*. The purpose of this study was to determine the effect of two types of temporary cement on pulpal blood flow (PBF) one day and seven days after full crown preparation and temporary cementation.

Materials and methods

Patient and tooth selection

The experiments were carried out on 20 second premolars in 18 subjects (age: 18-30 years, mean 23.1). All subjects had lost the mandibular first molar and needed a fixed prosthesis. All abutments were healthy, intact and had complete root formation, or if there was caries, the cavity depth was less than 0.5 mm into the dentine with absence of hypersensitivity. The teeth had no periodontal disease and the crown to root ratio of the abutments was at least 1:1.5. The study was approved by the Human Experimentation Committee, Faculty of Dentistry, Chiang Mai University (Certificate no. 39/2015), and complied with the Declaration of Helsinki principles. The experimental procedures were clearly explained and written informed consent was granted by all subjects. The privacy rights of the subjects were respected at all times.

Abutment preparation and temporary cementation

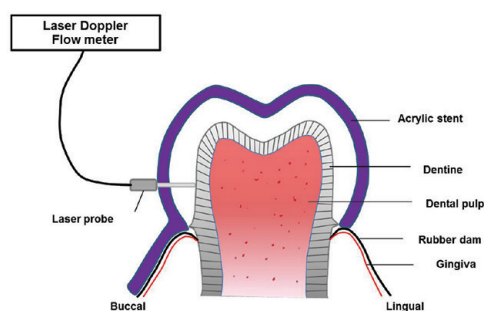
All the abutment teeth were prepared for full coverage of three-unit bridges by the same operator. The teeth and surrounding tissues were anesthetized with 4% articaine with epinephrine 1:100,000 (Ubistesin™ Forte, 3M ESPE, Seefeld, Germany) by an inferior alveolar nerve block, lingual nerve block and buccal nerve block technique. Five minutes after injection, the tooth structure was reduced approximately 1.0-1.5 mm from the enamel

surface under light pressure and water spray coolant. The occlusal and buccal surfaces were reduced by 1.5 mm, whereas the mesial, distal and lingual surfaces were reduced by 1 mm. The cervical finishing line of the preparation was a chamfer and was located slightly above the gingival margin to prevent creating gingival inflammation, which might have interfered with the recording of blood flow from the teeth. Before the final impression was taken, pulpal blood flow was measured, as described in the next paragraph. Then, the later procedures were performed following a standard protocol. After the preparation of the abutment teeth had been completed, a temporary bridge made of auto-polymerizing acrylic resin was fixed in place with two types of temporary cement. The temporary bridges were cemented to the abutment teeth with eugenol-containing temporary cement (Temp-Bond, Kerr Corporation, CA, USA.) (Group I, n=10) or non-eugenol temporary cement (Temp-Bond NE, Kerr Corporation) (Group II, n=10). After one day the temporary bridges were removed, the prepared teeth were cleaned with pumice, and the blood flow was measured. The temporary bridges were then re-cemented with the same type of temporary cement. Seven days after tooth preparation, these procedures were repeated. Following blood flow measurement, the permanent bridge was fixed with resin cement (RelyX™ U200, 3M ESPE).

Pulpal Blood flow Recording

Pulpal blood flow was recorded with a Moor Type MBF3D/42 blood flow monitor (Moor Instruments, Axminster, UK). During recording, opaque black rubber dam (Four D Rubber Co. Ltd., Heanor, UK) was applied on the teeth in order to reduce non-pulpal signal blood flow in tissues outside the tooth.⁽⁶⁾ The probe of the instrument (o.d. 1.5 mm) contains two 0.2 mm-diameter optical fibers with

their centers separated by 0.5 mm. The probe was stabilized to the tooth with an opaque acrylic stent. The stent was constructed from self-curing acrylic resin on a plaster model of the tooth. It covered the buccal, occlusal and lingual surfaces of the tooth and extended from the mandibular canine to the mandibular second molar. The holes to fit the probe were drilled through the stent 2 mm from the gingival margin so that the probe was perpendicular to the tooth surface and kept in the same location throughout the experiment (Fig 1). Pulpal blood flow was recorded from the second premolar abutments three times: after complete preparation of the abutments (day 0), after one day (day 1) and after seven days (day 7). The flux signal from the blood flow monitor was digitized by a CED micro1401-3 data acquisition unit, with the Spike II Program (Cambridge Electronic Design Limited, Cambridge, UK) and stored on a laptop computer for further analysis. The sensitivity of the blood flow signal was standardized and recordings were made with an upper bandwidth setting of 14.9 kHz and a time constant of 0.1 second. Blood flow was measured in arbitrary perfusion units (P.U.).⁽⁷⁾



รูปที่ 1 แผนภาพการติดตั้งการทดลองการบันทึกการไหลเวียนโลหิตของเนื้อเยื่อใน

Figure 1 Diagram of the experimental set up for pulpal blood flow recording.

After each experiment, records were made at different light intensities from a stationary reflector (white card) by inserting the probe tip at the end of a black and opaque plastic syringe. The white card was attached to the piston of the syringe. The piston was pulled slowly and stopped when the signal was stable for at least five seconds. The recorded data were used for calculating the offset of the blood flow signal that would have been present while recording from the teeth due to noise in the detection system.⁽⁸⁾ For each set of blood flow values recorded from the same tooth during the experiment, the mean and standard deviation (S.D.) were determined and calculated as described above with subtraction of the offset from the mean value.

Statistical analysis

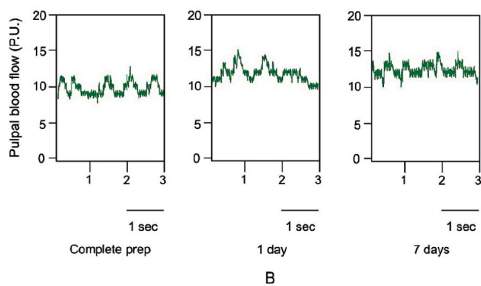
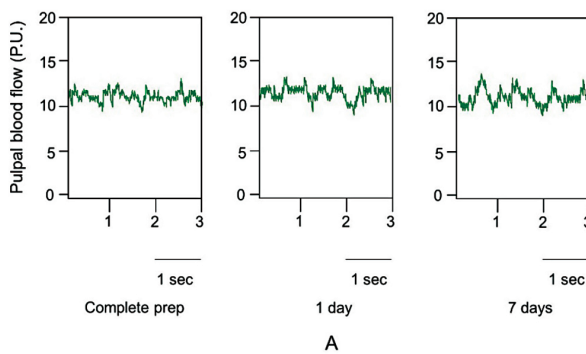
The mean pulpal blood flow values after complete preparation from each group were normalized to 100 to produce baseline values. The mean pulpal blood flow values on day 1 and day 7 from each group were adjusted compared to baseline values. The differences between the values recorded after complete preparation, day 1 and day 7 were compared using two-way, repeated measures analysis of variance (RM ANOVA). P values of less than 0.05 were considered significant. The statistical analyses were carried out with Sigmaplot[®] software (version 12, Systat Software Inc., CA, USA).

Results

The pulpal blood flow signals were recorded under three conditions from Groups I and II, as shown in Figure 2. The mean pulpal blood flow values after complete preparation, one and seven days after cementation from Group I and Group II were adjusted compared to baseline values from complete preparation, as shown in Figure 3. The

mean (\pm S.D.) pulpal blood flow values are presented in Table 1. The adjusted values were used to compare the statistical difference in pulpal blood flow after preparation and one day and seven days after cementation.

The mean pulpal blood flow after complete preparation and one day and seven days after cementation in Group I were not significantly different ($p > 0.05$, two-way RM ANOVA) (Fig.3). In Group II, the mean blood flow value seven days after cementation was significantly higher than that after one day and after complete preparation ($p = 0.042$ and $p < 0.001$, respectively, two-way RM ANOVA). The mean value after one day was not different from that after complete preparation. The mean



รูปที่ 2 ตัวอย่างการบันทึกการไหลเวียนโลหิตของเนื้อเยื่อในทันที่บันทึกด้วยเครื่องเลเซอร์ดอป-เพลอร์โฟลว์มิเตอร์ภายใต้สภาวะต่างๆ
A. กลุ่มที่ 1; B. กลุ่มที่ 2

Figure 2 Examples of records of pulpal blood flow with a laser Doppler flow meter under different conditions.
A. group I B. group II

รูปที่ 3

ค่าการไหลเวียนโลหิตของเนื้อเยื่อในทันที่ปรับแล้วเฉลี่ยและส่วนเบี่ยงเบนมาตรฐานในแต่ละกลุ่มเปรียบเทียบกับค่าที่ปรับฐานที่ได้จากการกรอฟันสมบูรณ์

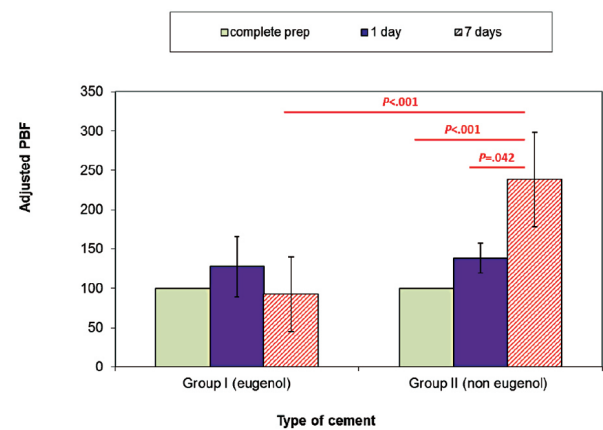
Figure 3 Adjusted mean (\pm S.D.) pulpal blood flow values from each set of data compared to baseline values from complete preparation.

pulpal blood flow seven days after cementation in Group II was significantly higher than that in Group I ($p < 0.001$) but there was no significant difference between Groups I and II one day after cementation.

Discussion

This experiment has shown that pulpal blood flow in the abutments increased significantly after one day and seven days when the temporary bridge was fixed with non-eugenol temporary cement but did not change when fixed with eugenol-containing temporary cement.

The increased pulpal blood flow in the non-eugenol temporary cement group in this study indicated that there was a certain degree of pulpal inflammatory response to the full crown preparation procedure. Our study was consistent with other studies in that the tooth preparation procedure caused postoperative irreversible pulpitis or pulp necrosis around 5%-25%.⁽⁹⁻¹¹⁾ Insufficient remaining dentine



ตารางที่ 1 ค่าการไหลเวียนโลหิตของเนื้อเยื่อในเฉลี่ยและส่วนเบี่ยงเบนมาตรฐานของกลุ่มที่ 1 (มียูจีนอลเป็นส่วนประกอบ) และกลุ่มที่ 2 (ไม่มียูจีนอลเป็นส่วนประกอบ)

Table 1 Mean (\pm S.D.) pulpal blood flow values from group I (eugenol) and II (non-eugenol).

Group	Mean (\pm S.D.) pulpal blood flow (P.U.)		
	complete prep	1 day	7 days
I (eugenol)	4.80 \pm 2.54	5.16 \pm 1.52	4.51 \pm 1.23
II (non-eugenol)	2.79 \pm 1.77	4.42 \pm 4.30	4.94 \pm 2.35

thickness, excessive pressure during preparation and inadequate water coolant were blamed to be the causes.

Pulpal inflammation following full crown preparation has been shown in many studies.⁽¹²⁻¹⁴⁾ The dental pulp becomes necrotic when cutting the tooth without sufficient water coolant.⁽¹²⁾ However, a mild pulpal response is still demonstrated even when cutting the tooth with adequate water spray.⁽¹³⁾ Excessive pressure during the cutting process also has the potential to cause pulpal injury, even more critical than with inadequate water coolant.⁽¹⁴⁾ If pressure applied from the hand-piece is greater than 8 oz, a pulpal reaction can be observed.

The slight increase in pulpal blood flow on day 1 and the decrease on day 7 in the eugenol group, although not significant suggests that the inflammation was reduced by the eugenol in the temporary cement. Furthermore, eugenol is claimed to have antimicrobial activity,⁽¹⁵⁻¹⁷⁾ anti-inflammatory properties,⁽¹⁷⁻¹⁹⁾ and bactericidal and analgesic effects.⁽¹⁵⁾ The slow release of eugenol from the temporary cement could reduce the inflammatory process by inhibiting PGE₂ and interleukin 1 β synthesis,⁽¹⁷⁾ nerve activity and white blood cell chemotaxis.⁽¹⁾

In our study, no toxic effect of eugenol was found, although it directly contacted the cut dentine surface for a week. Presumably, the remaining den-

tine thickness in this study was more than 1.0-1.5 mm, which was sufficient to prevent the cytotoxic properties of eugenol.⁽²⁰⁾ However, the histological condition of the specimens was impossible to analyze in a clinical study such as this.

Microleakage of the provisional bridges in our study caused significant increases in pulpal blood flow on day 7, as also found in the study of Lewinstein and colleagues.⁽²¹⁾ The bacteria and their toxins invade the dental pulp via the dentinal tubules from microleakage at the crown margin.⁽²²⁾

Although eugenol in the temporary cement has anti-inflammatory properties, it has been accused of interfering with resin polymerization and reducing surface hardness and bond strength of permanent resin cement.^(3,23) Such interferences in polymerization and reduction in surface hardness may influence the treatment plan of the dentist for using eugenol-containing temporary cement. However, the presence of residual cement might be the cause of the negative effects rather than the presence of eugenol.⁽²⁴⁾ The dentine surface should be completely cleaned prior to permanent cementation to improve bond strength of the resin cement and the restorations.

Nevertheless, more research needs to be conducted to provide solid evidence that either supports eugenol temporary cement because of its anti-inflammatory effect or refutes it because of its interference in the bonding of resin cement.

Conclusions

Eugenol-containing temporary cement stabilized the pulpal blood flow by reducing pulpal inflammation caused by full crown preparation in human subjects. On the other hand, there was an increase in pulpal blood flow following crown preparation when using a non-eugenol temporary cement.

Acknowledgements

The study was funded by the Faculty of Dentistry, Chiang Mai University, Thailand. The authors wish to thank Dr. M. Kevin O Carroll, Professor Emeritus of the University of Mississippi School of Dentistry, USA and Faculty Consultant at Chiang Mai University Faculty of Dentistry, Thailand, for his assistance in the preparation of the manuscript.

References

- Hume WR. An analysis of the release and the diffusion through dentin of eugenol from zinc oxide-eugenol mixtures. *J Dent Res* 1984; 63(6): 881-884.
- Yap AU, Shah KC, Loh ET, Sim SS, Tan CC. Influence of eugenol-containing temporary restorations on bond strength of composite to dentin. *Oper Dent* 2001; 26(6): 556-561.
- Fujisawa S, Kadoma Y. Action of eugenol as a retarder against polymerization of methymethacrylate by benzoyl peroxide. *Biomaterials* 1997; 18(9): 701-703.
- Gazelius B, Olgart L, Edwall B, Edwall L. Non-invasive recording of blood flow in human dental pulp. *Endod Dent Traumatol* 1986; 2(5): 219-221.
- Matthews B, Vongsavan N. Advantages and limitations of laser Doppler flow meters. *Int Endod J* 1993; 26(1): 9-10.
- Soo-ampon S, Vongsavan N, Soo-ampon M, Chuckpaiwong S, Matthews B. The sources of laser Doppler blood-flow signals recorded from human teeth. *Arch Oral Biol* 2003; 48(5): 353-360.
- Vongsavan N, Matthews B. Experiments on extracted teeth into the validity of using laser Doppler techniques for recording pulpal blood flow. *Arch Oral Biol* 1993; 38(5): 431-439.
- Vongsavan N, Matthews B. Some aspects of the use of laser Doppler flow meters for recording tissue blood flow. *Exp Physiol* 1993; 78(1): 1-14.
- Bergenholtz G, Nyman S. Endodontic complications following periodontal and prosthetic treatment of patients with advanced periodontal disease. *J Periodontol* 1984; 55(2): 63-68.
- Jackson CR, Skidmore AE, Ted-Rice R. Pulpal evaluation of teeth restored with fixed prostheses. *J Prosthet Dent* 1992; 67(3): 323-325.
- Cheung GSP, Lai SCN, Ng RPY. Fate of vital pulps beneath a metal-ceramic crown or a bridge retainer. *Int Endod J* 2005; 38(8): 521-530.
- Langeland K, Langeland LK. Pulp reactions to crown preparation, impression temporary crown fixation, and permanent cementation. *J Prosthet Dent* 1965; 15(1): 129-143.
- Seltzer S, Bender IB. Early human pulp reactions to full crown preparations. *J Am Dent Assoc* 1959; 59: 915-923.
- Stanley HR, Swerdlow H. Biological effects of various cutting methods in cavity preparation: the part pressure plays in pulpal response. *J Am Dent Assoc* 1960; 61: 450-456.
- Cox ST Jr, Hembree JH Jr, McKnight JP. The bactericidal potential of various endodontic materials for primary teeth. *Oral Surg Oral Med Oral Pathol* 1978; 45(6): 947-954.

16. Cobankara FK, Altinöz HC, Ergani O, Kav K, Belli S. In vitro antibacterial activities of root-canal sealers by using two different methods. *J Endod* 2004; 30(1): 57-60.
17. Anuj G, Sanjay S. Eugenol: a potential phytochemical with multifaceted therapeutic activities. *Pharmacologyonline 2* 2010; 2: 108-120.
18. Glass RL, Zander HA. Pulp healing. *J Dent Res* 1949; 28(2): 97-107.
19. Azuma Y, Ozasa N, Ueda Y, Takagi N. Pharmacological studies on the anti-inflammatory action of phenolic compounds. *J Dent Res* 1986; 65(1): 53-56.
20. Abou Hashieh I, Camps J, Dejoui J, Franquin JC. Eugenol diffusion through dentin related to dentin hydraulic conductance. *Dent Mater* 1998; 14(4): 229-236.
21. Lewinstein I, Fuhrer N, Gelfand K, Cardash H, Pilo R. Retention, marginal leakage, and cement solubility of provisional crowns cemented with temporary cement containing stannous fluoride. *Int J Prosthodont* 2003; 16(2): 189-193.
22. Goldman M, Laosonthorn P, White RR. Microleakage--Full crowns and the dental pulp. *J Endod* 1992; 18(10): 473-475.
23. Terata R, Nakashima K, Obara M, Kubota M. Characterization of enamel and dentin surfaces after removal of temporary cement—effect of temporary cement on tensile bond strength of resin luting cement. *Dent Mater J* 1994; 13(2): 148-154.
24. Woody TL, Davis RD. The effect of eugenol-containing and eugenol-free temporary cements on microleakage in resin bonded restorations. *Oper Dent* 1992; 17(5): 175-180.